

CONTENTS

CHAPTER ONE

Introduction to the Classification of Lymphoma	1
<i>Martin C. Mihm, Cynthia M. Magro, and A. Neil Crowson</i>	
Kiel, Lukes–Collins, and Working Formulation Classifications, 1	
WHO, Real, and EORTC Classifications, 2	
Summary, 6	
References, 7	
Appendix: Definitions of Key Terms and Techniques, 8	

CHAPTER TWO

The Therapy of Cutaneous T Cell Lymphoma	14
<i>Pierluigi Porcu and Mark A. Bechtel</i>	
Introduction, 14	
Diagnostic Work-up and Staging Procedures, 15	
Goals of Therapy in Advanced Stage CTCL, 15	
Extracorporeal Photopheresis (ECP), 15	
Interferons, 16	
Retinoids, 16	
Immunotoxins, 17	
Monoclonal Antibodies, 17	
Cytotoxic Chemotherapy, 18	
Investigational Therapies, 18	
<i>Monoclonal Antibodies</i> , 19	
<i>TLR Agonists and Cytokines</i> , 19	
<i>Histone Deacetylase Inhibitors (HDACi)</i> , 19	
<i>Allogeneic Hematopoietic Stem Cell Transplantation (allo-HSCT)</i> , 20	
CTCL Therapies, 20	

<i>Skin-Directed Therapies</i> , 20	
References, 23	

CHAPTER THREE

Molecular Techniques	25
<i>Carl Morrison</i>	
Introduction, 25	
Immunoglobulin Receptor Structure, 26	
<i>IgH</i> , 26	
<i>TCR-β</i> , 27	
<i>PCR Design for Determination of Clonality</i> , 27	
Detection of PCR Products for Clonality, 27	
<i>Evaluation of Results</i> , 29	
Limitations of Clonality Assessment by PCR, 30	
Summary, 31	
References, 32	

CHAPTER FOUR

Benign Lymphocytic Infiltrates	33
<i>Cynthia M. Magro and A. Neil Crowson</i>	
Introduction, 33	
Spongiotic and Eczematous Dermatitis, 33	
<i>Allergic Contact Dermatitis</i> , 33	
<i>Pityriasis Rosea</i> , 36	
<i>Pityriasis Rosea-like Drug Reaction</i> , 37	
Other Spongiotic/Eczematous Tissue Reactions, 37	
<i>Photoallergic Reactions</i> , 37	
Other Causes of Subacute Eczematous Dermatitis, 38	
<i>Nummular Eczema</i> , 38	
<i>Small Plaque Parapsoriasis</i> , 39	

<i>Pruritic Urticarial Plaques and Papules of Pregnancy</i> , 39	
<i>Superficial Erythema Annulare Centrifugum</i> , 39	
Interface Dermatitis: Cell-Poor Vacuolar Interface Dermatitis, 40	
<i>Erythema Multiforme</i> , 40	
<i>Gianotti–Crosti Syndrome (Popular Acrodermatitis of Childhood)</i> , 42	
<i>Acute Graft-Versus-Host Disease</i> , 42	
<i>Morbiliform Viral Exanthem and Morbiliform Drug Eruption</i> , 44	
<i>Collagen Vascular Disease Compatible with Antibody-Dependent Cellular Immunity and/or Anti endothelial Cell Antibodies</i> , 44	
Interface Dermatitis: Lichenoid Pattern, 46	
<i>Lichen Planus</i> , 46	
<i>Lichen Planus-like Eruptions of Hepatobiliary Disease</i> , 47	
<i>Lichen Planus-like Eruptions of Secondary Syphilis</i> , 48	
<i>Lichenoid Drug Reactions</i> , 48	
<i>Lichenoid Connective Tissue Disease Syndromes</i> , 48	
<i>Lichenoid (“Chronic”) Graft-Versus-Host Disease</i> , 51	
Diffuse and Nodular Lymphocytic Dermal Infiltrates Without Atypia, 52	
<i>Polymorphous Light Eruption as the Prototypic Type IV Immune Reaction</i> , 52	
<i>Other Dermal Perivascular Lymphocytic Infiltrates</i> , 54	
<i>Gyrate Erythemas</i> , 54	
Diffuse and Nodular Lymphocytic Infiltrates Associated with Autoimmune Disease, 55	
<i>Nonscarring Discoid Lupus Erythematosus/Tumid Lupus Erythematosus</i> , 55	
<i>Morphea</i> , 56	
<i>Jessner’s Lymphocytic Infiltrate of the Skin</i> , 58	
References, 60	
CHAPTER FIVE	
Reactive Lymphomatoid Tissue Reactions Mimicking Cutaneous T and B Cell Lymphoma	63
<i>Cynthia M. Magro and A. Neil Crowson</i>	
<i>Lymphomatoid Drug Eruptions</i> , 64	
<i>Molecular Profile of Lymphomatoid Drug Eruptions</i> , 66	
<i>Pathogenetic Basis of Lymphomatoid Drug Reactions</i> , 67	
<i>Reactive Lymphomatoid Lesions Encountered in Lesions of Collagen Vascular Disease</i> , 68	
<i>Lymphomatoid Lupus Erythematosus</i> , 68	
<i>Pathogenesis of Lymphomatoid Tissue Response in Collagen Vascular Disease</i> , 69	
<i>Lupus Erythematosus Profundus</i> , 69	
<i>Viral-Associated Lymphomatoid Dermatitis</i> , 70	
<i>Lymphocytoma Cutis</i> , 70	
<i>Primary Cutaneous Plasmacytosis</i> , 71	
<i>Conclusion</i> , 72	
<i>Case Vignettes</i> , 73	
<i>References</i> , 89	
CHAPTER SIX	
Precursor Lesions of Cutaneous T Cell Lymphoma	93
<i>Cynthia M. Magro, Joan Guitart and A. Neil Crowson</i>	
<i>Cutaneous T Cell Lymphoid Dyscrasia</i> , 93	
<i>Large Plaque Parapsoriasis</i> , 94	
<i>Hypopigmented Epitheliotropic T Cell Dyscrasia/Hypopigmented Large Plaque Parapsoriasis as a Precursor Lesion to Hypopigmented Mycosis Fungoides</i> , 96	
<i>Pigmented Purpuric Dermatitis (PPD)</i> , 97	
<i>Pityriasis Lichenoides Chronica</i> , 100	
<i>Syringolymphoid Hyperplasia with Alopecia</i> , 103	
<i>Idiopathic Follicular Mucinosis/Alopecia Mucinososa</i> , 104	
<i>Atypical Lymphocytic Lobular Panniculitis</i> , 106	
<i>Case Vignettes</i> , 109	
<i>Additional Molecular and Cytogenetic Studies</i> , 126	
<i>References</i> , 138	
CHAPTER SEVEN	
Marginal Zone Lymphoma and Other Low-Grade B Cell Lymphoproliferative Disorders of the Skin	141
<i>Cynthia M. Magro and A. Neil Crowson</i>	
<i>Marginal Zone Lymphoma</i> , 141	
<i>Castleman’s Disease</i> , 148	
<i>Primary Cutaneous Plasmacytoma</i> , 149	
<i>Case Vignettes</i> , 151	
<i>References</i> , 170	

CHAPTER EIGHT

- Primary Cutaneous Follicle Center Cell Lymphoma** 173
Cynthia M. Magro and A. Neil Crowson
 Case Vignettes, 178
 Additional Molecular and Cytogenetic Study, 190
 References, 191

CHAPTER NINE

- Primary Cutaneous Diffuse Large B-Cell Lymphoma and Precursor Lymphoblastic Lymphoma** 192
Cynthia M. Magro and A. Neil Crowson
Primary Cutaneous Diffuse Large B-Cell Lymphoma, 192
Cutaneous Precursor B Cell Lymphoblastic Lymphoma/Lymphoblastic Leukemia (Precursor B Cell Acute Lymphoblastic Leukemia), 198
 Case Vignettes, 203
 Additional Molecular and Cytogenetic Studies, 213
 References, 216

CHAPTER TEN

- Intravascular Lymphoma** 219
Cynthia M. Magro and A. Neil Crowson
 Case Vignette, 222
 References, 224

CHAPTER ELEVEN

- Chronic Lymphocytic Leukemia of B Cell and T Cell Phenotype (T Cell Prolymphocytic Leukemia)** 226
Cynthia M. Magro and A. Neil Crowson
B Cell Chronic Lymphocytic Leukemia, 226
T Cell Prolymphocytic Leukemia, 228
 Case Vignettes, 231
 Additional Molecular and Cytogenetic Studies, 244
 References, 246

CHAPTER TWELVE

- Cutaneous Mantle Cell Lymphoma** 248
Cynthia M. Magro and A. Neil Crowson
 Case Vignettes, 252
 Additional Molecular and Cytogenetic Studies, 256
 References, 257

CHAPTER THIRTEEN

- Primary Cutaneous $\gamma\delta$ T Cell Lymphoma** 259
Cynthia M. Magro and A. Neil Crowson
 Introduction, 259
 Case Vignette, 264
 References, 266

CHAPTER FOURTEEN

- Mycosis Fungoides** 267
Cynthia M. Magro, Martin C. Mihm, and A. Neil Crowson
 Definition, 267
 Historical Perspective, 267
 Demographics, 267
 Clinical Presentation, 267
Patch Stage, 268
Plaque Stage, 270
Tumor Stage, 270
Extracutaneous Dissemination, 271
 Clinical Variants, 271
Papuloerythroderma, 271
Mycosis Fungoides in Childhood, 271
Adnexotropic Mycosis Fungoides, 272
Woringer-Kolopp Disease (Pagetoid Reticulosis), 272
Granulomatous Slack Skin/Granulomatous Mycosis Fungoides, 273
Sezary Syndrome, 273
 Extracutaneous Involvement in Mycosis Fungoides, 285
 Phenotypic Profile, 286
 Molecular Profile, 288
 Cytogenetics, 288
 Pathogenesis, 288
 Case Vignettes, 290
 Additional Molecular and Cytogenetic Studies, 292
 References, 297

CHAPTER FIFTEEN

- Primary Cutaneous Pleomorphic Small/Medium Sized T-Cell Lymphoma And Peripheral T-Cell Lymphoma, Unspecified, Presenting in the SKIN (CD30-Negative Large Cell T Cell Lymphoma)** 300
Cynthia M. Magro and A. Neil Crowson
 Case Vignettes, 306

Additional Molecular and Cytogenetic Study, 315
References, 316

CHAPTER SIXTEEN

Adult T Cell Leukemia/Lymphoma 318
Cynthia M. Magro
Case Vignettes, 322
References, 327

CHAPTER SEVENTEEN

Angioimmunoblastic Lymphadenopathy (AILD)/Angioimmunoblastic T Cell Lymphoma 329
Cynthia M. Magro and A. Neil Crowson
Case Vignettes, 334
References, 340

CHAPTER EIGHTEEN

CD8 T Cell Lymphoproliferative Disease of the Skin 343
Cynthia M. Magro and A. Neil Crowson
Introduction, 343
Primary Cutaneous CD8 Lymphoma, 343
CD8 Variant of Lymphomatoid Papulosis and Other Related CD30-Positive T Cell Lymphoproliferative Disorders of CD8 Subtype, 346
CD8 Prolymphocytic Leukemia, 347
CD8 Pseudolymphoma Related to Underlying HIV Disease, 348
CD8 Cytotoxic Pseudolymphoma Related to Drug Therapy, 348
Case Vignettes, 349
References, 364

CHAPTER NINETEEN

Subcutaneous Panniculitis-Like T Cell Lymphoma 366
Cynthia M. Magro and A. Neil Crowson
Case Vignettes, 372
References, 379

CHAPTER TWENTY

Epstein–Barr Virus-Associated Lymphoproliferative Disease 381
Cynthia M. Magro and A. Neil Crowson
Introduction, 381
Hydroa Vacciniforme-Like EBV-Associated T Cell Lymphoproliferative Disease/Mosquito Bite Hypersensitivity, 382

Epstein–Barr Virus-Associated B Cell Lymphoproliferative Disease in the Setting of Iatrogenic Immune Dysregulation, 384

Case Vignettes, 390
References, 395

CHAPTER TWENTY-ONE

Nasal and Related Extranodal Natural Killer Cell/T Cell Lymphomas 399
Cynthia M. Magro and A. Neil Crowson
Introduction, 399
Biology of NK and NK-like T Cells, 401
NK/T-Cell Lymphoma, 402
Nasal NK/T-Cell Lymphoma, 402
Nasal Type NK/T Cell Lymphoma, 403
Aggressive NK Cell Lymphoma, 403
Role of Epstein–Barr Virus in the Evolution of NK/T Cell Lymphomas, 406
Blastic/Blastoid NK Cell Lymphoma/Agranular CD4-positive CD56-positive Hematodermic Neoplasm, 406
Panniculitis-like T Cell Lymphoma Showing CD56 Positivity, 406
Chronic Granular Lymphocytosis/Large Granular Cell Leukemia, 407
Natural Killer-like T Cell Lymphoma of the CD4 Subset: A Rare Variant of Natural Killer Cell Lymphoma to Be Distinguished from the Hematodermic Neoplasm, 408
Case Vignettes, 410
References, 425

CHAPTER TWENTY-TWO

Lymphomatoid Granulomatosis (LYG) 429
Cynthia M. Magro and A. Neil Crowson
Introduction, 429
Case Vignette, 434
References, 437

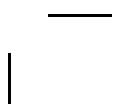
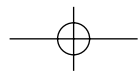
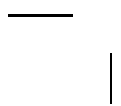
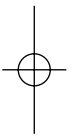
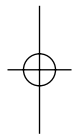

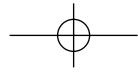

CHAPTER TWENTY-THREE

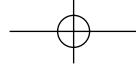
CD30-Positive Lymphoproliferative Disorders Including Lymphomatoid Papulosis, Borderline CD30-Positive Lymphoproliferative Disease, Anaplastic Large Cell Lymphoma, and T-Cell-Rich CD30-Positive Large B Cell Lymphoma 439
Cynthia M. Magro and A. Neil Crowson
Introduction, 439
Lymphomatoid Papulosis, 440
CD8 Lymphomatoid Papulosis, 444

Borderline CD30-Positive Lymphoproliferative Disorders (Type C LYP) (Case Vignette 9), 445
Cutaneous Anaplastic Large Cell Lymphoma, 445
CD30-Positive Large B Cell Lymphoma, 450
Case Vignettes, 452
Additional Molecular and Cytogenetic Studies, 468
References, 471

CHAPTER TWENTY-FOUR

Primary Cutaneous Hodgkin Lymphoma 475
Cynthia M. Magro
Subtypes of Hodgkin Lymphoma, 477
Classic Hodgkin Lymphoma, 477
Lymphocyte-Predominant Hodgkin lymphoma, 477
Case Vignette, 480
Additional Molecular and Cytogenetic Studies, 484
References, 486
Index, 489





The Cutaneous Lymphoid Proliferations

