

1 Cutaneous anatomy and function

Robert P. Chilcott

Chemical Hazards and Poisons Division, Centre for Radiation, Chemical and Environmental Hazards, Chilton, Oxfordshire OX11 0RQ, UK

Primary Learning Objectives

- *Appreciation of the highly variable morphology of the skin, particularly between anatomical regions (intra-individual variation) and between species.*
- *Basic understanding of the functional anatomy of the epidermis in relation to skin barrier properties.*

1.1 Introduction and scope

In terrestrial mammals, the integument contributes to a variety of physiological functions including thermoregulation, immune defence and the prevention of catastrophic water loss. It is the barrier property of skin that is of specific relevance to dermal toxicology (dermatotoxicology), so the purpose of this chapter is to outline the anatomical and histological features that contribute to skin barrier function. Therefore, this chapter concentrates on the outermost (epidermal) layers associated with protecting the skin from the ingress of xenobiotics. More detailed information on the structure and function of the dermis and hypodermis may be found elsewhere (Forslind *et al.* 2004; Freinkel and Woodley 2001; Montagna 1962).

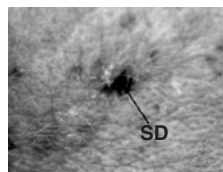
1.2 Surface features

The skin is not a homogenous covering. Its structure and function vary considerably, resulting in regional variations in permeability that may span several orders of magnitude.

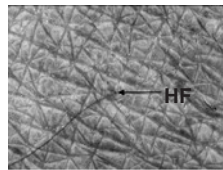
The protective function of the human integument is reflected by its relatively small surface area ($\sim 2 \text{ m}^2$). In contrast, the lung and gastrointestinal tract have evolved to facilitate absorption and so have much higher surface areas (~ 150 and 200 m^2 , respectively).

Human skin can essentially be divided into two types; glabrous (non-hairy) and non-glabrous. The former is generally thicker and less permeable than the latter and is limited to areas such as the palms of the hand, soles of the feet and lips.

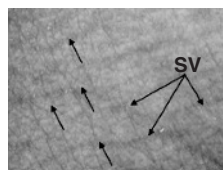
Skin surface morphology varies according to anatomical region and this is particularly evident in humans where localised, functional adaptations have resulted in overt differences in appearance (Figure 1.1). Regional differences include variation in epidermal thickness and the density of hair follicles, sweat and sebaceous ducts (Table 1.1). Other differences include the presence or absence of ridges and sulci (dermatoglyphs), flexure lines, surface roughness and extent of oily (sebaceous) deposits. It is conceivable that the presence of furrows, wrinkles or dermatoglyphs may affect the skin surface distribution of liquids applied to the skin by providing a means for capillary motion away from the point of contact, thus facilitating skin surface spreading and so increasing the area of skin contamination (Figure 1.2). However, the influence of the skin surface micro-relief on skin absorption has not been thoroughly investigated. The human integument is also characterised by lines of cleavage referred to as Langer's lines, which result from the (congenital) orientation of collagen fibres within the dermis. The lines of Langer are of clinical significance in surgical procedures: incisions made



(A)



(B)



(C)

Figure 1.1 Skin surface over the inner ear (A), hand (dorsum) (B) and wrist (ventral aspect) (C). Some dermatoglyphs are discernible on the inner ear site, but the main feature of the picture is the enlarged sebaceous duct (SD) specific to this anatomical region. The duct is surrounded by fine (velous) hairs, which provide some limited protection against foreign objects. Dermatoglyphics are pronounced on the back of the hand and are occasionally punctuated by hair follicles (HF) sprouting hair of medium coarseness. The wrist area is largely free of hair but flexure lines (indicated by small arrows) can be clearly seen running in parallel. Also visible are superficial veins (SV) of this region. Photographs courtesy of Dr Helen Packham, Enviroderm Services. A full-colour version of this figure appears in the colour plate section of this book

Table 1.1 Selection of quantitative data of human skin characteristics

Anatomical Location	Thickness		Turnover (days)	Kinetics		Appendageal Density		Temperature ($^{\circ}\text{C}$)	Surface Lipids ($\mu\text{g cm}^{-2}$)
	Epidermis (μm)	Dermis (μm)		Desquamation ($\text{g m}^{-2} \text{day}^{-1}$)	Glands (cm^{-2})	Follicles (cm^{-2})			
Finger	547	1207				0–50			
Thigh	61	1298		0.3	55		31.3	5	
Forearm	53	1118	13	0.1			32.1	6	
Abdomen	42	2163	9.6		70		32.6		10
Thorax	51	1676			75		32.7		
Axilla	44	1186			65	100			7
Back	71	2326	15		65				
Pubis	45	1014							
Sole	1159	1534							
Face	52	2271			700			12	
Forehead	82	1500	6.3	1.7	765	400–900	34.3	24	
Palms	575	1100	30	3.5					
Scalp			9.6	2.1	350				

Turnover (kinetics) refers to the average time taken for a cell in the stratum basale to reach the stratum corneum.

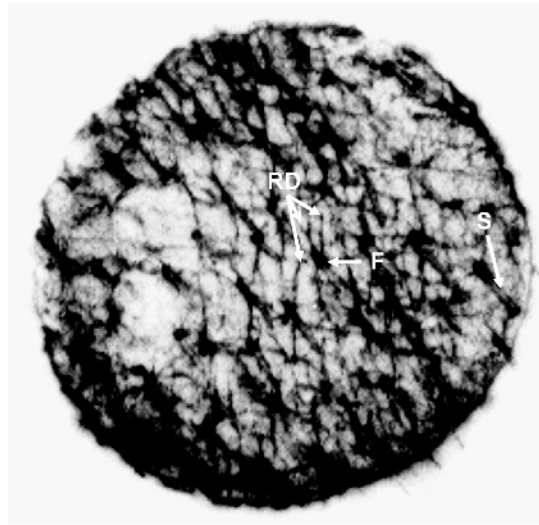


Figure 1.2 Surface autoradiograph of pig skin exposed to a single, discrete droplet (100 μ l) of 14 C-radiolabelled benzene under unoccluded conditions. Radioactive material (indicated by the dark areas) can be seen to preferentially partition into hair follicles (F) and hair shafts (S). Dermatoglyphics can be seen radiating from (and interconnecting) adjacent hair follicles (RD), indicative of capillary movement along the sulci

parallel to Langer's lines generally heal more readily and are less likely to form scar tissue (Monaco and Grumbine 1986).

Numerous studies have demonstrated that skin permeability is also subject to anatomical variation (Feldmann and Maibach 1967, Maibach *et al.* 1971, Rougier *et al.* 1986). Whilst epidermal thickness is commonly considered to be a prime determinant of regional skin permeability, such generalisations should be interpreted with caution (for example, see Figure 1.3) as other factors such as the regional lipid content (Table 1.1) or morphology of the stratum corneum may be implicated (Rougier *et al.* 1988).

There is a superficial 'layer' of skin that is often overlooked in dermal toxicology: the 'acid mantle'. This forms a thin film on the skin surface and is comprised of sebum, corneocyte debris and residual material from sweat. This mixture of substances generally imparts a low pH on the skin surface owing to the presence of free fatty acids and, being predominantly lipophilic, may conceivably influence the partitioning of substances into the skin or act as an adsorbent matrix to trap microscopic particles such as dirt, dust or powders.

The predominant component of the acid mantle is sebum, considered by some to be vestigial (Kligman 1963). Sebum is mainly composed of triglycerides, wax esters and squalene, with the actual composition (and amount being secreted) varying according to anatomical location (Figure 1.4).

The evolutionary significance of sebum has been subject to much debate and several putative functions including anti-microbial activity, 'water-proofing' and 'sweat-sheet' formation have been proposed (Porter 2001). However, sebum may represent a significant route of excretion for lipophilic substances (Faergemann *et al.* 1993; Iida *et al.* 1999) and may be of physiological significance for the delivery of vitamin E to the skin surface where it could act as a superficial antioxidant (Thiele *et al.* 1999).

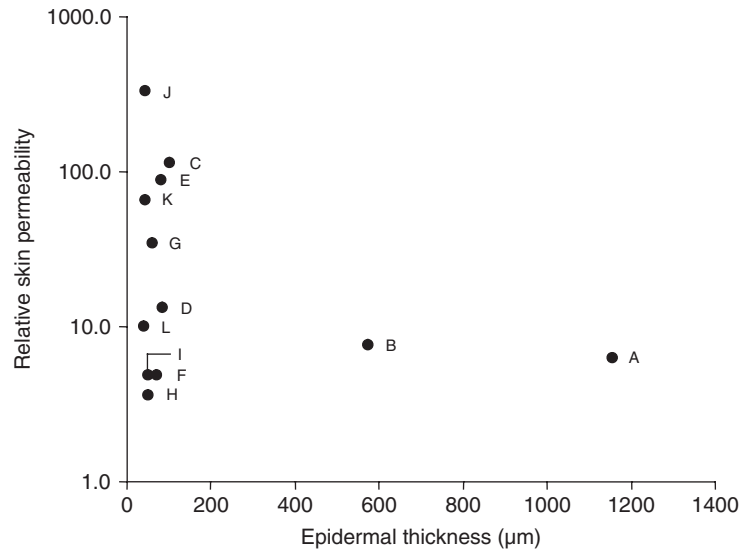


Figure 1.3 Epidermal thickness as a function of skin permeability (expressed relative to the least permeable site, the back of the hand) measured in human volunteers to the nerve agent VX (O-ethyl-S-[2(diisopropylamino)ethyl] methylphosphonothioate). Anatomical regions (in order thickest to thinnest): A = plantar; B = palmar; C = cheek; D = nape of neck; E = forehead; F = back; G = groin; H = forearm (ventral aspect); I = forearm (dorsal aspect); J = scrotum; K = axilla; L = abdomen

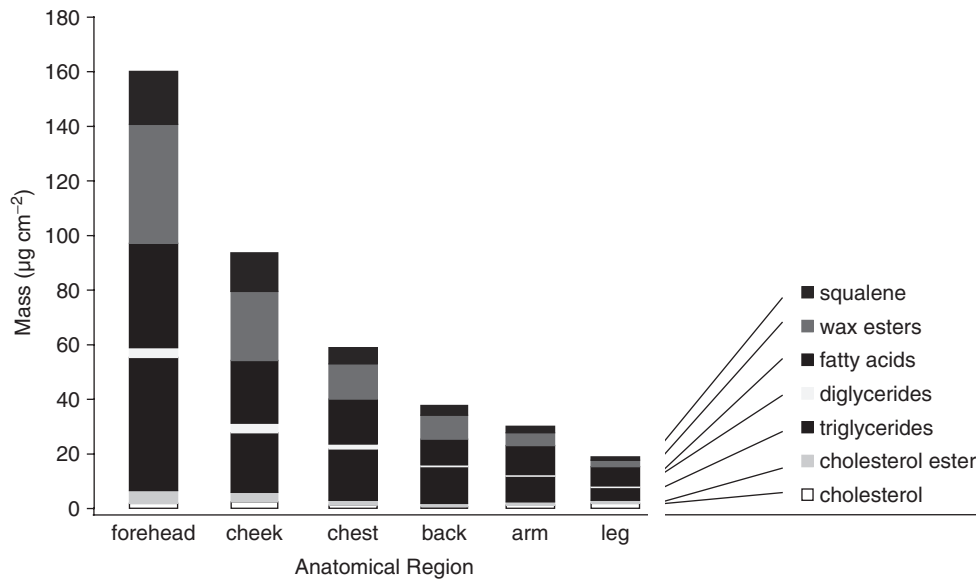


Figure 1.4 Quantity and composition of sebum, according to anatomical location (Greene *et al.* 1970, Reprinted by permission from Macmillan Publishers Ltd)

Clearly, the distribution and composition of the acid mantle will be dictated to some degree by the regional distribution of sweat and sebaceous glands. The former are found in highest abundance on palmar–plantar regions where the latter are absent. Sebaceous glands are generally associated with hair follicles, though in some areas such as the nipples, labia minora and prepuce, they open directly onto the skin surface. The highest densities of sebaceous glands are found on the scalp and face, with the forehead secreting the largest quantity of sebum per unit area of skin (Snyder *et al.* 1981).

It is possible that certain protocols involved in preparing skin tissue for *in vitro* absorption studies may alter the characteristics of the acid mantle. For example, the practice of briefly immersing skin in hot water (a standard method for the preparation of epidermal membranes) may perturb or remove the acid mantle from the skin surface. Consequently, this could affect partitioning of chemicals into the skin and so alter skin absorption kinetics.

1.3 Functional histology of the epidermis and associated structures

The upper layer of the skin (epidermis) is mainly responsible for providing protection against the ingress of chemicals and is subject to a cycle of renewal which takes 5–30 days.

The skin is a multi-layered (veneered or stratified) structure comprising three principal layers, namely, the epidermis, dermis (corium) and hypodermis (Figure 1.5). In general, the epidermis accounts for ~5% of the combined thickness of human epidermis and dermis except in regions that are exposed to physical stress such as palmar-plantar skin where the proportion of epidermis is ~60% (Table 1.1). The epidermis provides protection against xenobiotics,

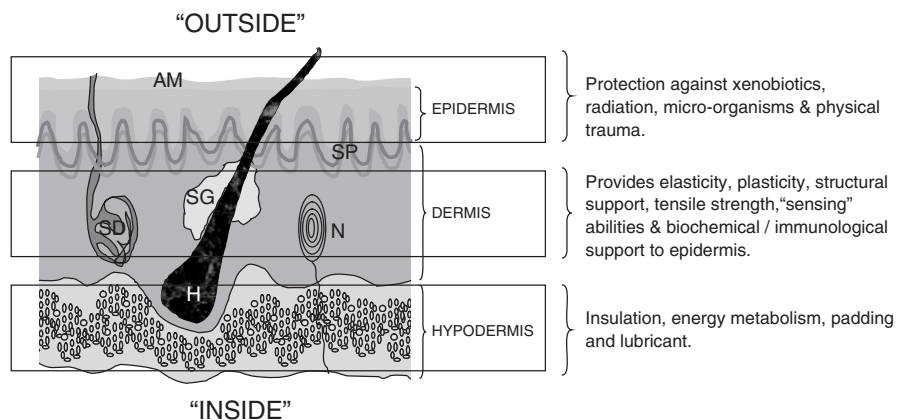


Figure 1.5 Schematic representation of skin structure and associated functions. Note that the relative thickness of each layer is not to scale (see text). Several adnexal structures are shown (SP = superficial plexus; SG = sebaceous gland; SD = sweat duct; N = Pacinian corpuscle; H = hair). In humans the skin is covered with a thin layer of lipids known as the acid mantle (AM), which comprises sebum, cell debris and sweat residua. A full-colour version of this figure appears in the colour plate section of this book

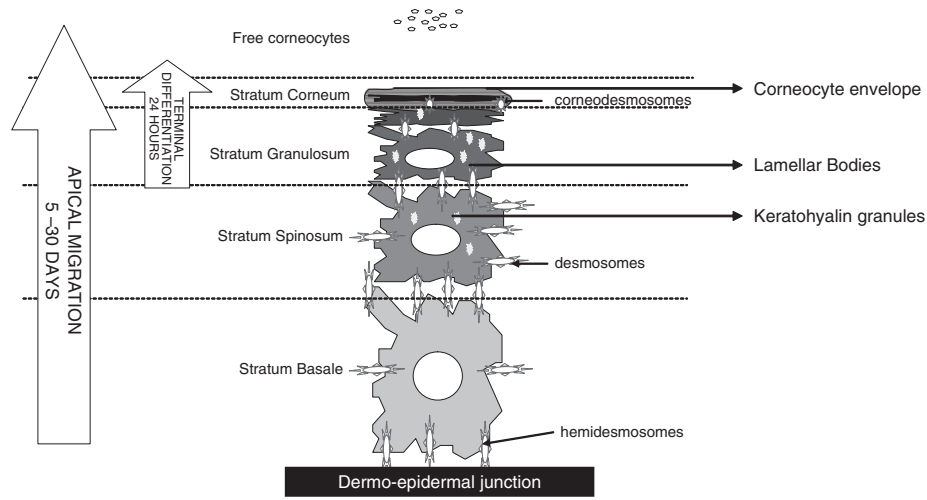


Figure 1.6 Schematic representation of individual cells of the epidermis. The basal cells (anchored to the dermo-epidermal junction via hemidesmosomes) undergo apical migration towards the skin surface whilst undergoing a process of differentiation. The first stage of differentiation results in the appearance of spinous cells (stratum spinosum) in which adjacent cells are interconnected by tight junctions (desmosomes). Keratohyaline granules, which contain profilaggrin (which facilitates the bundling of keratin in later stages of terminal differentiation) and filaggrin (the putative precursor of natural moisturising factor, NMF), begin to appear. The production of lamellar bodies is consistent with the formation of the stratum granulosum, exocytosis of which forms the lipid matrix in which corneocytes are embedded. During apical migration, cohesion of desmosomes is gradually degraded by the action of enzymes culminating the loss (sloughing) of free corneocytes thereby regulating the thickness of the stratum corneum

micro-organisms, some forms of radiation and, to a limited extent, mechanical trauma. Most of these functions are fulfilled by the stratum corneum, the outermost layer of the skin.

The epidermis is predominantly (>90%) populated by keratinocytes that continuously undergo apical migration from the stratum basale. During migration, keratinocytes undergo several stages of differentiation, which can be identified histologically as the stratum spinosum, stratum granulosum and stratum corneum (Figure 1.6). In regions where the epidermis is thicker, an additional layer (between the stratum granulosum and the stratum corneum) termed the stratum lucidum may be observed.

The nomenclature of the different epidermal layers reflects position or cellular morphology (Figure 1.6). Basal cells are sited at the base of the epidermis. Cells of the stratum spinosum radiate small spines, though this appearance is now thought to be an artefact of the light microscope rather than a definitive structural feature. Cells of the stratum granulosum have inclusion bodies (precursors of the lipid matrix of the stratum corneum) that impart a granular appearance.

Occasionally, older terminology may be found in the literature (Table 1.2). For example, the basal and spinosum layers may be referred to as the stratum Malpighii (after the Italian physician Marcello Malpighi, circa 1628–1694).

Apical migration and differentiation, from basal cell to fully formed corneocyte, takes approximately 5–30 days (Figure 1.6), depending on anatomical region (Table 1.1). In

Table 1.2 Alternative histological nomenclature of the epidermal layers, with typical thickness measurement (for human skin)

Current Nomenclature	Thickness (μm)	Alternative Nomenclature
Stratum corneum	10–20	Horny layer
Stratum granulosum		Granular layer
Stratum spinosum	50–100	Prickle cell/spinous layer, acanthocyte (refers to individual cell)
Stratum basal		Stratum germinativum, rootlets

contrast, the final stage of (terminal) differentiation may occur in less than 24 hours and enables prompt repair of superficial damage to the stratum corneum. The gradual degradation of cell–cell adhesion (mediated via desmosomes) ultimately leads to loss of corneocytes (sloughing) and can account for up to one gramme of material (the main constituent of ‘house dust’) per adult per day (Snyder *et al.* 1981).

Other types of cell present in the epidermis include Langerhans cells (involved with antigen presentation) and melanocytes (which synthesise the photo-protectant, melanin). The mobile nature of these two (dendritic) cell types enables them to migrate and populate the interstitial space between keratinocytes, and there is growing evidence that melanocytes, Langerhans and keratinocytes form functional units within the epidermis (Nordlund and Boissy 2001). Indeed, melanocytes interact with a predefined number of keratinocytes within the basal epidermis (the so-called melanocyte–keratinocyte unit) according to set ratios depending on constitutive (normal) skin colour (Seiberg 2001). The role of melanocytes and Langerhan’s cells are considered in more detail in Chapters 3 and 10, respectively.

The outmost layer of the epidermis, the stratum corneum, is the predominant barrier layer. This property arises from the arrangement of cornified cells embedded in a lipid matrix known as the ‘brick and mortar’ structure.

Terminally differentiated keratinocytes of the stratum corneum are known as corneocytes and are largely devoid of normal cellular functions, being predominantly composed of protein (keratin) and a remnant of the original cell wall (‘corneocyte envelope’).

The ultrastructure of the stratum corneum is described by the ‘brick and mortar model’ (Michaels *et al.* 1975). The functional implication of this architecture is that some skin penetrants must diffuse via a long and tortuous route between adjacent corneocytes, thus reducing their rate of absorption. This is known as the intercellular route (Figure 1.7). In contrast, some chemicals may diffuse equally through both corneocytes and the lipid mortar, resulting in a transcellular route (Figure 1.7). Both inter and intracellular routes are collectively known as bulk pathways. A third, potential route of entry across the skin involves diffusion down hair follicles and into sebaceous glands or via sweat ducts (Figure 1.7). These are referred to as ‘shunt pathways’ and their contribution to skin absorption is currently a contentious issue. Historically, the relative role of the shunt and bulk transport pathways have been likened to an army crossing marshland that contains a few narrow bridges: whilst a small number of

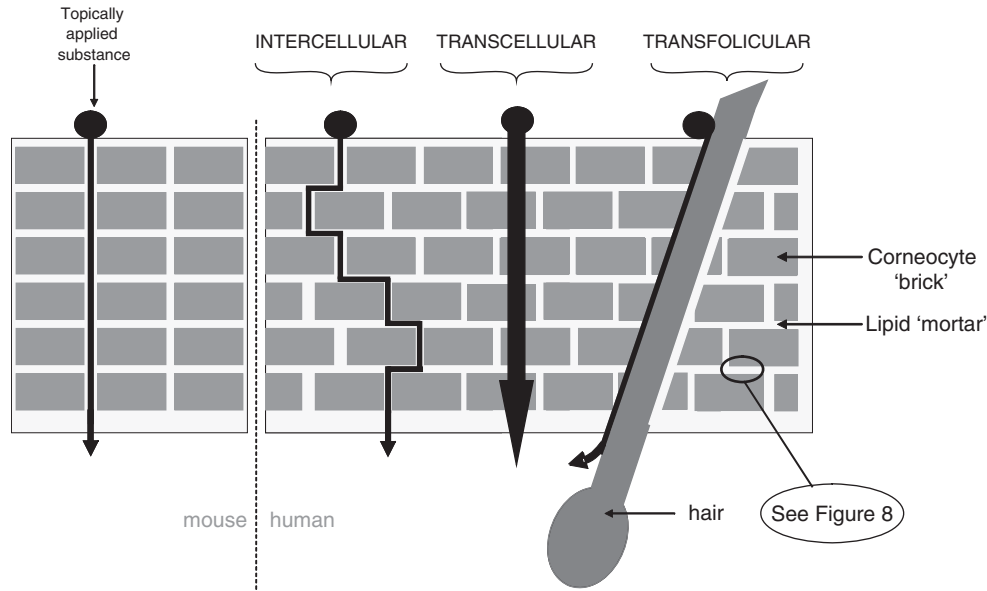


Figure 1.7 Schematic representation of arrangement of corneocytes in mouse and human stratum corneum ('brick and mortar' model). The stacked (columnar) arrangement of corneocytes in mouse stratum corneum facilitates a relatively short route for diffusion. In contrast, the oblique arrangement of corneocytes in human stratum corneum compels molecules (diffusing via the intercellular route) to take a long and tortuous route. The two other routes of entry (transcellular and transfolicular) are shown for comparison. The structure of the lipid mortar is detailed in Figure 1.8

soldiers can rapidly march across the bridges in single file, the majority have to trudge slowly through the boggy ground (Scheuplein 1976). This analogy pertains to the relatively small surface area occupied by hair follicles. For example, the average width of a scalp hair is $\sim 50 \mu\text{m}$ and this region contains ~ 300 hair follicles per cm^2 . Thus, the total surface area occupied by hair follicles per cm^2 of scalp skin is exceedingly small: approximately 0.007 cm^2 . However, this does not take into account the fact that a hair follicle is a three dimensional structure that penetrates deep into the dermis. Assuming that an average hair follicle is $500 \mu\text{m}$ deep (and approximates in shape to a cylinder), then the total surface area of hair follicles per cm^2 can be calculated to be $\sim 0.95 \text{ cm}^2$. Thus, on the scalp at least, the presence of hair follicles essentially doubles the surface area available for skin absorption.

Skin appendages such as hair follicles provide a potential 'short-cut' for skin absorption by penetrating directly into the dermis. However, the practical relevance of such shunt pathways is of some considerable debate.

It is important to note that such shunt pathways are not the biological equivalent of intergalactic wormholes and do not provide a paranormal route of entry into the skin. Hair follicles and other appendageal structures are generally lined with cornified cells and so diffusion from the follicle into the dermis is still subject to the same barrier layer as is present on the skin surface.

Furthermore, the follicles are usually full of very lipophilic material (sebum) and so effectively exclude hydrophilic substances or partition and bind very lipophilic materials. Thus, the appearance of a chemical within hair follicles in the dermal region of skin does not equate to dermal delivery: the substance is still on the outside of the body! However, it should be noted that for some chemicals (hydrophilic, charged molecules; Chapter 6), the shunt pathways may represent the predominant route of penetration, although the overall rate of absorption of such compounds is generally very low. The relative contribution of each transport pathway is discussed in more detail in Chapter 5.

Whilst corneocytes can be considered to be hydrophilic domains, they are surrounded by a lipid-rich matrix mainly comprising ceramides, free fatty acids and cholesterol (Downing *et al.* 1987). Thus, the intercellular domain is predominantly a lipophilic environment. This combination imparts a degree of 'amphiphobicity' upon the stratum corneum, providing limited protection against both lipophilic and hydrophilic penetrants. The composition and underlying metabolism of stratum corneum lipids (as opposed to the skin surface lipids discussed above) is reviewed in Chapter 2.

The molecular packing of the lipid matrix within the inter-corneocyte spaces effectively sets an upper limit on the physical size of molecules that may penetrate the stratum corneum (Figure 1.8). This is referred to as the 'rule of 500' (Bos and Meinardi 2000) since few substances with a molecular weight above 500 Da are capable of passive diffusion through the skin. However, recent studies suggest that ultra-fine particles (also termed nanoparticles)

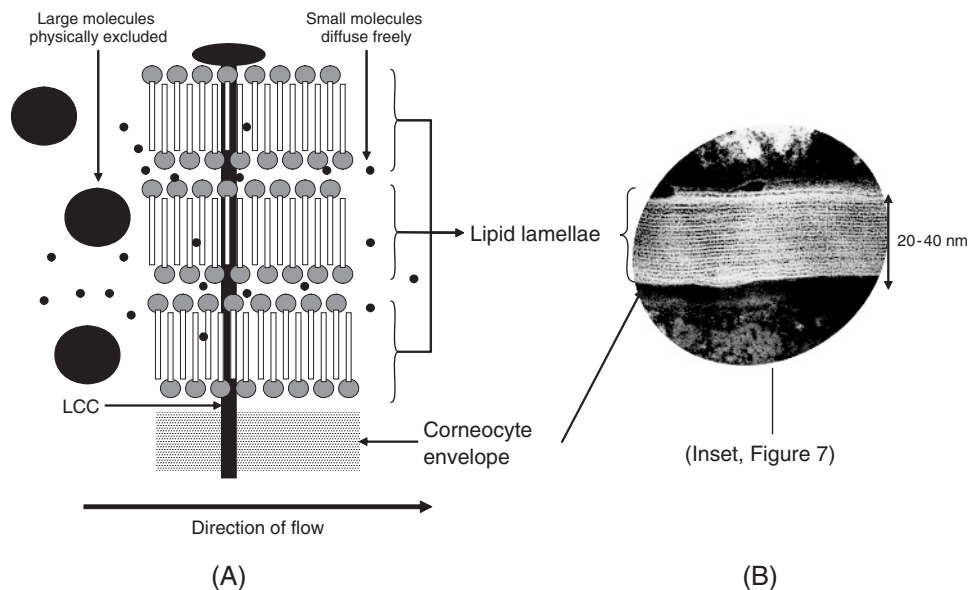


Figure 1.8 Arrangement of lipid lamellae within the inter-corneocyte space of the stratum corneum. (A) Empirical representation of adjacent lipid layers showing the physical exclusion of large molecules. The lamellae are 'riveted' to the outer corneocyte envelope by a long-chain ceramide (LCC). (B) Electron micrograph of the inter-corneocyte domain, demonstrating the lipid lamellar packing (courtesy of Professor Joke Bouwstra, University of Leiden, The Netherlands)

have the potential to penetrate the stratum corneum (Ryman-Rasmussen *et al.* 2006). Whilst this is largely unexpected in terms of molecular weight, the diameter of such particles is less than the distance that separates adjacent corneocytes and thus diffusion through the stratum corneum is plausible. Given current health concerns over the increasing use of nanoparticles in consumer products, it is likely that a great deal more research will be conducted in this relatively new area.

The epidermis is anchored to the dermis via a continuous, protein-rich region termed the dermo-epidermal junction. This structure is highly invaginated and forms characteristic ('rete') ridges on skin sections that are readily discernible under the light microscope. The underlying blood supply (superficial plexus) interdigitates with the rete ridges, thus providing a large surface area for the bi-directional transfer of nutrients, oxygen and waste products. Chemicals that are able to traverse the epidermis are generally subject to systemic absorption by the superficial (papillary) plexus at this anatomical region (Figure 1.5) and so the dermis and hypodermis are not generally relevant to the percutaneous absorption kinetics of many substances. However, if the peripheral blood supply (i.e. the superficial plexus) is reduced by vasoconstriction, systemic uptake may be diminished, resulting in accumulation of penetrant within the dermal tissue; conversely, vasodilation may increase systemic uptake from the superficial plexus (Brain *et al.* 2006, Rommen *et al.* 1999). Alternatively, the 'ground substance' of the dermis essentially represents an aqueous gel environment and this will provide an additional barrier to the ingress of strongly lipophilic substances (Flynn *et al.* 1981). Therefore, it is important when conducting *in vitro* skin absorption studies to select the most appropriate tissue preparation: epidermal membranes are arguably the most relevant model since penetration through this layer *in vivo* results in contact with the circulatory system (superficial plexus; see Figure 1.5). The presence of dermal tissue in dermatomed skin is therefore representative of an additional barrier that is not normally present *in vivo* and may lead to an underestimate of skin absorption for lipophilic substances (Chapter 9).

1.4 Species differences

Human skin is remarkable in many respects from most other mammals and this is of relevance to the interpretation of toxicological data obtained from animal models such as the rat, mouse and guinea pig.

The most obvious difference between human and animal models is pelage density (Figure 1.9): a thick coat of hair provides a substantial degree of protection against the ingress of xenobiotics and exposure to radiation. As a possible consequence of this evolutionary divergence, the stratum corneum of rodents and lagomorphs is generally more permeable and considerably more fragile than 'naked' species such as pig and human (see legend, Figure 1.9). This difference is manifest when preparing tissue samples for *in vitro* skin absorption studies: human and (to some extent) pig skin can be used to prepare strong, coherent sheets of stratum corneum or epidermis that retain their physical durability for several months at room temperature. In contrast, it is practically impossible to produce similar tissue preparations for rodent skin, although limited success can be achieved with sodium bromide separation of neonatal rat skin (Scott *et al.* 1986). This species difference in pelage density between human and rodent skin is

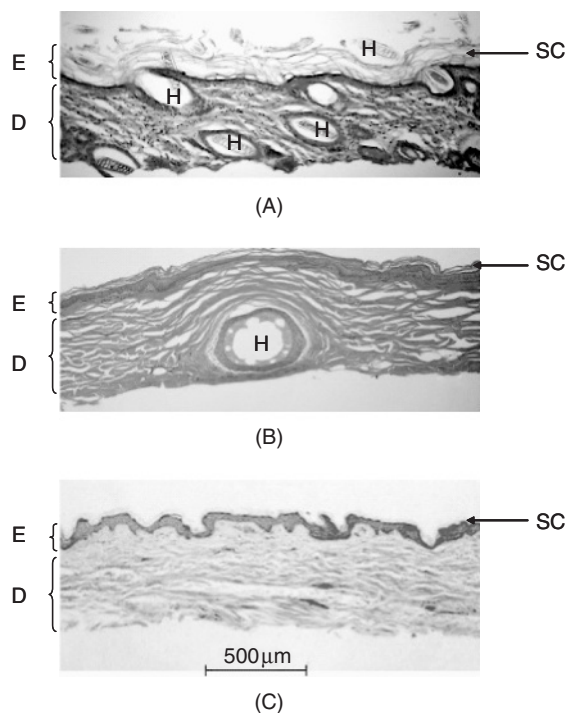


Figure 1.9 Representative sections of dermatomed guinea pig (A), pig (B) and human (C) skin. Two principal layers are discernible in each section: the epidermis (E) and dermis (D). Note that guinea pig stratum corneum (SC) appears as an incoherent, flaky layer whereas SC of pig and human retains a flatter, more compact appearance. A large number of hairs (H) are present in the guinea pig section. A full-colour version of this figure appears in the colour plate section of this book

of particular relevance when interpreting toxicological studies, especially if the test substance has demonstrable affinity for hair or associated (appendageal) structures.

Animal skin also contains a layer of muscle (*panniculus carnosus*), which is largely absent in humans with the exception of the *platysma*, situated over the ventral aspect of the neck. This is of relevance when conducting *in vitro* skin absorption studies with full thickness animal skin, as the *panniculus carnosus* represents an additional barrier layer to diffusion (although this can be avoided by the use of skin dermatomed to an appropriate thickness).

Mouse skin is generally more permeable than human and most other species. This may in part be attributable to the arrangement of corneocytes within the stratum corneum (Bergstresser and Chapman 1980). In human skin, corneocytes are normally offset between adjacent rows and this provides a tortuous route for intercellular transport. In contrast, murine corneocytes are arranged in columns (stacks) and so may offer a more direct route for the ingress of xenobiotics (Figure 1.7).

From a histological perspective, the pig (*sus scrofa*) is the species that bears most resemblance to human (Figure 1.9) and so the use of strains with reduced growth rates (such as the Göttingen minipig[®]) are becoming increasingly common in toxicological and pharmacological studies.

Summary

- Human skin presents a barrier to the ingress of many xenobiotics and has a correspondingly low surface area in comparison with other externalised organs such as the lung and gastrointestinal tract.
- The integument cannot be considered to be a homogeneous organ as there are substantial regional (anatomical) differences in structure and function such as permeability (which may span several orders of magnitude).
- There are three principal skin layers: epidermis, dermis and hypodermis. The former is primarily responsible for maintaining skin barrier function.
- The relative impermeability of the skin results from the structure and composition of the stratum corneum (the outermost layer of the epidermis), which is subject to a continuous cycle of regeneration through apical migration and terminal differentiation of epidermal cells (keratinocytes).
- There is considerable species variation in skin structure and function. The pig is arguably the most relevant animal model although rodents are currently the species of choice for toxicological evaluation.

References

- Bergstresser, P.R. and Chapman, S.L. (1980). Maturation of normal human epidermis without an ordered structure. *Br J Dermatol* **102**(6): 641–8.
- Bos, J.D. and Meinardi, M.M. (2000). The 500 Dalton rule for the skin penetration of chemical compounds and drugs. *Exp Dermatol* **9**(3): 165–9.
- Brain, K.R., Green, D.M., Dykes, P.J. *et al.* (2006). The role of menthol in skin penetration from topical formulations of ibuprofen 5% *in vivo*. *Skin Pharmacol Physiol* **19**(1): 17–21.
- Downing, D.T., Stewart, M.E., Wertz, P.W. *et al.* (1987). Skin lipids: an update. *J Invest Dermatol* **88**(3 Suppl): 2s–6s.
- Faergemann, J., Zehender, H., Denouel, J. and Millerioux, L. (1993). Levels of terbinafine in plasma, stratum corneum, dermis–epidermis (without stratum corneum), sebum, hair and nails during and after 250 mg terbinafine orally once per day for four weeks. *Acta Derm Venereol* **73**(4): 305–9.
- Feldmann, R.J. and Maibach, H.I. (1967). Regional variation in percutaneous penetration of ¹⁴C cortisol in man. *J Invest Dermatol* **48**(2): 181–3.
- Flynn, G.L., Durrheim, H. and Higuchi, W.I. (1981). Permeation of hairless mouse skin II: membrane sectioning techniques and influence on alkanol permeabilities. *J Pharm Sci* **70**(1): 52–6.
- Forslind, B., Lindberg, M. and Norlen, L. (eds). (2004). *Skin, hair, and nails*. Marcel Dekker Inc., New York.
- Freinkel, R.K. and Woodley, D.T. (eds). (2001). *The biology of the skin*. The Parthenon Publishing Group, London.
- Greene, R.S., Downing, D.T., Pochi, P.E. and Strauss, J.S. (1970). Anatomical variation in the amount and composition of human skin surface lipid. *J Invest Dermatol* **54**(3): 240.
- Iida, T., Hirakawa, H., Matsueda, T., *et al.* (1999). Recent trend of polychlorinated dibenzo-p-dioxins and their related compounds in the blood and sebum of Yusho and Yu Cheng patients. *Chemosphere* **38**(5): 981–93.
- Kligman, A.M. (1963). The Uses of Sebum. *Br J Dermatol* **75**(August/September): 307–319.

- Maibach, H.I., Feldman, R.J., Milby, T.H. and Serat, W.F. (1971). Regional variation in percutaneous penetration in man. *Pesticides. Arch Environ Health* **23**(3): 208–211.
- Michaels, A.S., Chandrasekaran, S.K. and Shaw, S.E. (1975). Drug permeation through human skin: Theory and *in vitro* experimental measurement. *AIChE Journal* **21**(5): 985–996.
- Monaco, A. and Grumbine, N.A. (1986). Lines of minimal movement. *Clin Podiatr Med Surg* **3**(2): 241–247.
- Montagna, W. (ed.). (1962). *The structure and function of skin*. Academic Press, New York.
- Nordlund, J.J. and Boissy, R.E. (2001). The biology of melanocytes, in *The biology of the skin* (eds Freinkel, R.K. and Woodley, D.T.). The Parthenon Publishing Group., New York, pp. 113–131.
- Porter, A.M. (2001). Why do we have apocrine and sebaceous glands? *J R Soc Med* **94**(5): 236–7.
- Rommen, C., Leopold, C.S. and Lippold, B.C. (1999). Do local anesthetics have an influence on the percutaneous penetration of a model corticosteroid? An *in vivo* study using the vasoconstrictor assay. *Eur J Pharm Sci* **9**(2): 227–34.
- Rougier, A., Dupuis, D., Lotte, C.R., *et al.* (1986). Regional variation in percutaneous absorption in man: measurement by the stripping method. *Arch Dermatol Res* **278**(6): 465–9.
- Rougier, A., Lotte, C., Corcuff, T.P. and Maibach, H.I. (1988). Relationship between skin permeability and corneocyte size according to anatomic site, age and sex in man. *J Society of Cosmetic Chemists* **39**(1): 15–26.
- Ryman-Rasmussen, J.P., Riviere, J.E. and Monteiro-Riviere, N.A. (2006). Penetration of intact skin by quantum dots with diverse physicochemical properties. *Toxicol Sci* **91**(1): 159–65.
- Scheuplein, R.J. (1976). Percutaneous absorption after twenty-five years: or ‘old wine in new wineskins’. *J Invest Dermatol* **67**(1): 31–8.
- Scott, R.C., Walker, M. and Dugard, P.H. (1986). *In vitro* percutaneous absorption experiments: a technique for the production of intact epidermal membranes from rat skin. *J Society of Cosmetic Chemists* **37**(1): 35–41.
- Seiberg, M. (2001). Keratinocyte–melanocyte interactions during melanosome transfer. *Pigment Cell Res* **14**(4): 236–42.
- Snyder, W.S., Cook, M.J., Karhausen, L.R. *et al.* (eds). (1981). *Report of the task group on reference man*. A. Wheaton & Co Ltd, Exeter.
- Thiele, J.J., Weber, S.U. and Packer, L. (1999). Sebaceous gland secretion is a major physiologic route of vitamin E delivery to skin. *J Invest Dermatol* **113**(6): 1006–10.