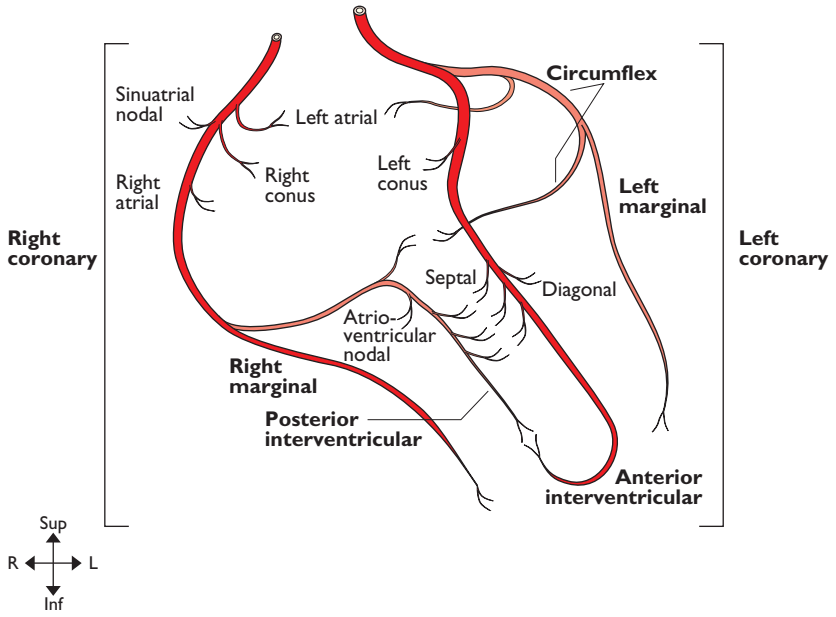

I: ARTERIES

Coronary arteries	2	Thoracic (descending) aorta	28
Ascending & arch of aorta	4	Abdominal aorta	30
Internal carotid artery, vertebrobasilar system & circle of Willis	8	External iliac artery	30
Ophthalmic artery	10	Coeliac trunk	32
External carotid artery	12	Superior mesenteric artery	34
Maxillary artery	14	Inferior mesenteric artery	34
Middle meningeal artery	14	Internal iliac artery	36
Subclavian artery	16	Femoral artery	36
Axillary artery	20	Popliteal artery	38
Brachial artery	22	Anterior tibial artery	38
Radial artery	24	Posterior tibial artery	40
Ulnar artery	26	Fibular (peroneal) artery	42
		Arterial anastomoses around scapula	44
		Arterial anastomoses around hip	45

COPYRIGHTED MATERIAL



Coronary arteries

CORONARY ARTERIES

From: Ascending aorta

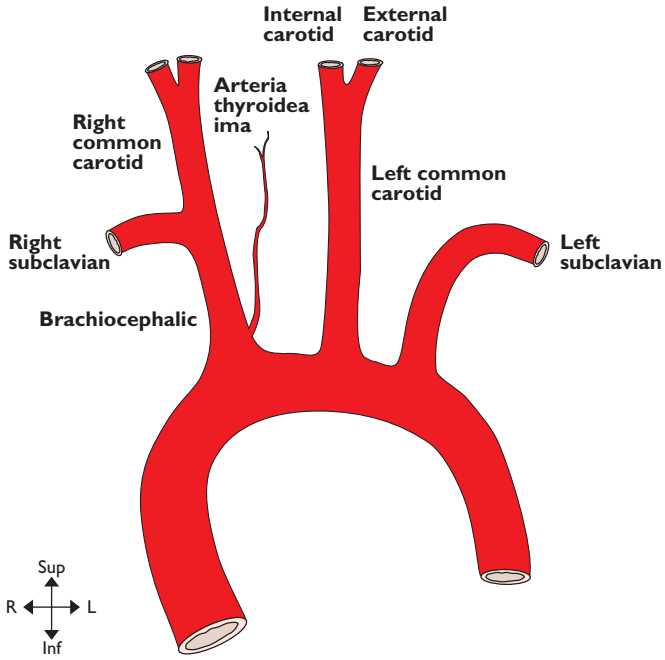
To: Myocardium

Right coronary artery. Originates from the anterior aortic sinus. It passes anteriorly between the pulmonary trunk and the right auricle to reach the atrioventricular sulcus in which it runs down the anterior surface of the right cardiac border and then onto the inferior surface of the heart. It terminates at the junction of the atrioventricular sulcus and the posterior interventricular groove by anastomosing with the circumflex branch of the left coronary artery and giving off the posterior interventricular (posterior descending) artery. It supplies the right atrium and part of the left atrium, the sinoatrial node in 60% of cases, the right ventricle, the posterior part of the interventricular septum and the atrioventricular node in 80% of cases.

Left coronary artery. Arises from the left posterior aortic sinus. It passes laterally, posterior to the pulmonary trunk and anterior to the left auricle to reach the

atrioventricular groove where it divides into an anterior interventricular (formally left anterior descending) artery and circumflex branches. The circumflex artery runs in the atrioventricular sulcus around the left border of the heart to anastomose with the right coronary artery. The anterior interventricular artery descends on the anterior surface of the heart in the anterior interventricular groove and around the apex of the heart into the posterior interventricular groove where it anastomoses with the posterior interventricular branch of the right coronary artery. The left coronary artery supplies the left atrium, left ventricle, anterior interventricular septum, sinoatrial node in 40% of cases and the atrioventricular node in 20%.

Dominance. In approximately 10% of hearts the posterior interventricular artery arises from the circumflex artery (left coronary) and then most of the left ventricle and interventricular septum are supplied by the left coronary artery. The heart is said to have *left cardiac dominance*.



Ascending & arch of aorta

ASCENDING & ARCH OF AORTA

From: Left ventricle

To: Descending aorta

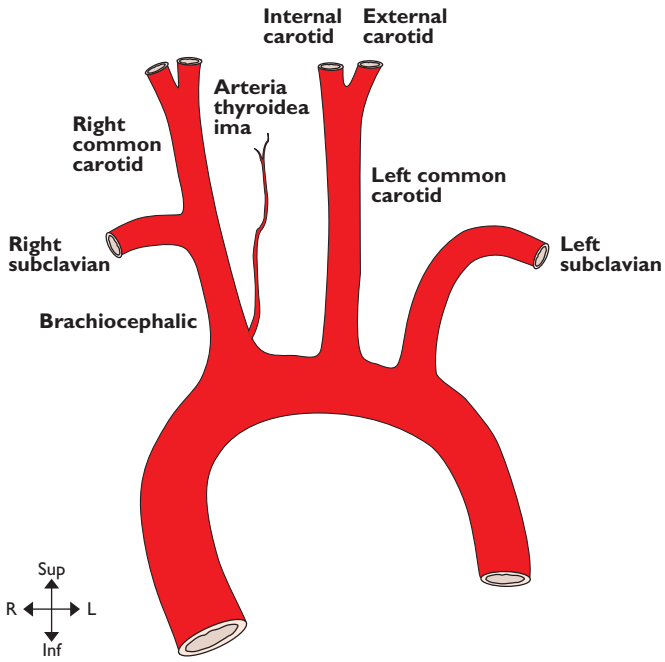
Ascending aorta. Arises at the vestibule of the left ventricle at the level of the third left costal cartilage and passes upwards and slightly to the right to a point behind the sternum at the level of the manubriosternal joint (second costal cartilage) where it becomes the arch of the aorta. It is enclosed in fibrous and serous pericardium. Anterior to it are the right auricle, the infundibulum of the right ventricle and pulmonary trunk. Posterior, lie the left atrium, the right pulmonary artery and right main bronchus. To the left lie the pulmonary trunk and the left auricle. To the right are the superior vena cava and the right atrium.

Arch of aorta. The arch begins posterior to the manubriosternal joint at the level of the second costal cartilage and passes posterior and to the left, over the left main bronchus to end at the left side of the body of T4 vertebra. Its highest level is the mid point of the manubrium sterni and at this level its three main branches emerge. Anterior and to the left of the arch are (from anterior to posterior) the left phrenic nerve, vagal and sympathetic contributions to the cardiac plexus, and the left vagus. Also, the left superior intercostal vein runs forwards on the arch anterior to the vagus and posterior

to the phrenic nerve. Lateral to all these structures are the pleura and left lung. Posterior and to the right of the arch are the trachea, deep cardiac plexus, left recurrent laryngeal nerve, oesophagus, thoracic duct and the body of T4. Inferior to the arch are the pulmonary bifurcation, the left main bronchus, the ligamentum arteriosum and the left recurrent laryngeal nerve. From its superior surface emerge the brachiocephalic artery, the left common carotid and left subclavian arteries. Within the adventitia of the ascending and arch of the aorta lie baro- and chemoreceptors.

Brachiocephalic artery. Arises from the convexity of the aortic arch behind the manubrium sterni and passes upwards and posteriorly to the right. It divides into the right subclavian and right common carotid arteries posterior to the right sternoclavicular joint. Anterior to it are the left brachiocephalic vein with the right inferior thyroid vein entering it, and the thymic remnants. The artery initially lies anterior to the trachea then passes to lie on its right lateral side. On the right of the artery are the right brachiocephalic vein, upper part of the superior vena cava, the pleura and the cardiac branches of the vagus. The main vagal trunk is more posterolateral. At the origin of the brachiocephalic artery the left common carotid artery lies posteriorly on its left.

continued



Ascending & arch of aorta

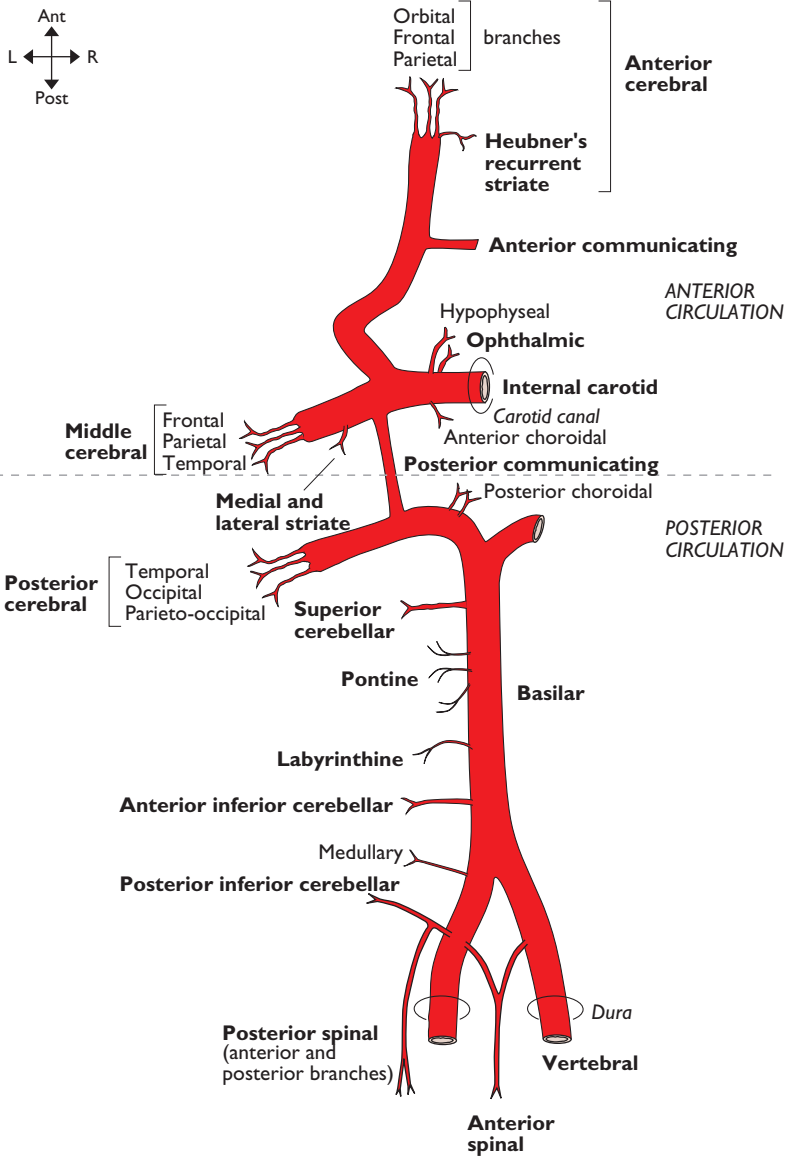
Common carotid arteries. The right common carotid artery arises from the brachiocephalic artery as it divides posterior to the right sternoclavicular joint, whilst the left common carotid arises from the convexity of the aortic arch. Both end as the arteries bifurcate at the level of the upper border of the thyroid cartilage (C4).

Left common carotid artery (thorax). Lying anterior to the thoracic part of this artery are the left brachiocephalic vein and the thymic remnant. Posterior to it in its lower part are the left subclavian artery and the trachea whilst further superiorly there is the left recurrent laryngeal nerve, the thoracic duct and the left side of the oesophagus. On its right at its origin is the brachiocephalic artery but as it ascends the inferior thyroid veins and the trachea come to lie on its right

side. To its left lie the vagus, the left phrenic nerve and the left pleura and lung.

Both common carotid arteries (cervical).

Ascend in the neck slightly laterally from a point posterior to the sternoclavicular joint to end at the level of the upper border of the thyroid cartilage (C4) at which point there is a dilatation—the carotid sinus (a baroreceptor). On the posterior aspect of the bifurcation there is the carotid body (a chemoreceptor). Lying between left and right arteries, and medial to each, progressively from below are the trachea, recurrent laryngeal nerves, thyroid gland, larynx and pharynx. Each artery lies in its carotid sheath with the internal jugular vein lateral to it and the vagus nerve between and posterior to them both.



Internal carotid, vertebrobasilar system & circle of Willis

Note: (1) Labyrinthine usually arises from anterior inferior cerebellar; (2) posterior spinal may come from vertebral

**INTERNAL CAROTID ARTERY,
VERTEBROBASILAR SYSTEM &
CIRCLE OF WILLIS**

From: Bifurcation of the common carotid
arts (C4) & first parts of subclavian arts
To: Terminal brs

The internal carotid artery angles from the bifurcation slightly posteriorly to reach the carotid canal through which it enters the skull to end as middle and anterior cerebral arteries. At its origin it possesses a dilatation in which lie the carotid sinus and body. In the neck it is crossed laterally by, from below up, the pharyngeal branch of the vagus (X), glossopharyngeal nerve (IX), stylopharyngeus and styloglossus. It lies on the pharyngeal wall and the pharyngobasilar fascia. Within the carotid canal it turns 90 degrees anteromedially to run through the petrous temporal bone where it lies medial to the middle ear. It then turns 90 degrees superiorly to pass across the upper limit of the foramen lacerum. It then turns 90 degrees anteriorly to pass forwards, lateral to the body of the sphenoid which it grooves. Here it lies in the medial wall of the cavernous sinus with the abducent nerve (VI) on its lateral side. At the anterior end of the cavernous sinus it turns 90 degrees superiorly then 90 degrees posteriorly to pass medial to the anterior clinoid process and lateral to the pituitary stalk and optic chiasma. It ends as terminal branches on the medial surface of the temporal lobe.

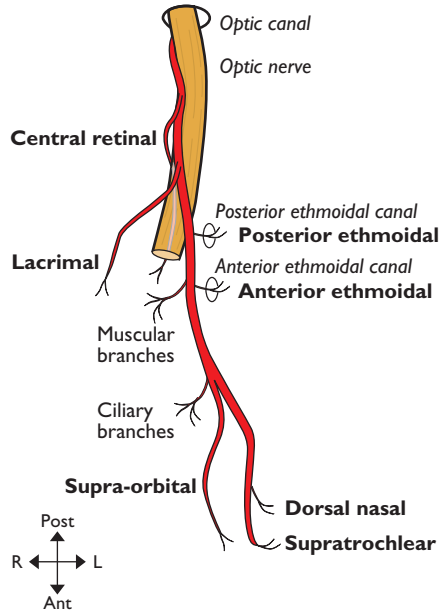
Anterior cerebral artery is formed by the bifurcation of the internal carotid artery. It passes anteriorly over the optic nerve to arch over the genu of the corpus callosum on the medial aspect of the cerebral hemispheres where it ends as terminal branches.

Middle cerebral artery is formed by the bifurcation of the internal carotid artery. It runs laterally into the sylvian fissure then posterosuperiorly in the sulcus where it divides into terminal branches.

Basilar artery is formed by the junction of the left and right vertebral arteries (see subclavian artery, pp. 16–19) anterior to the upper medulla. From there it ascends lying angled forwards between the pons and the clivus in a slight depression on the anterior surface of the pons. It terminates at the upper border of the pons as posterior cerebral arteries.

Posterior cerebral artery is formed by the bifurcation of the basilar artery. It passes laterally around the cerebral peduncle to run posteriorly above the tentorium cerebelli on the inferomedial surface of the occipital lobe where it divides into terminal branches.

(Other branches of the internal carotid artery, not illustrated, are caroticotympanic, pterygoid and cavernous arteries.)



Ophthalmic artery

Note: Right side viewed from above

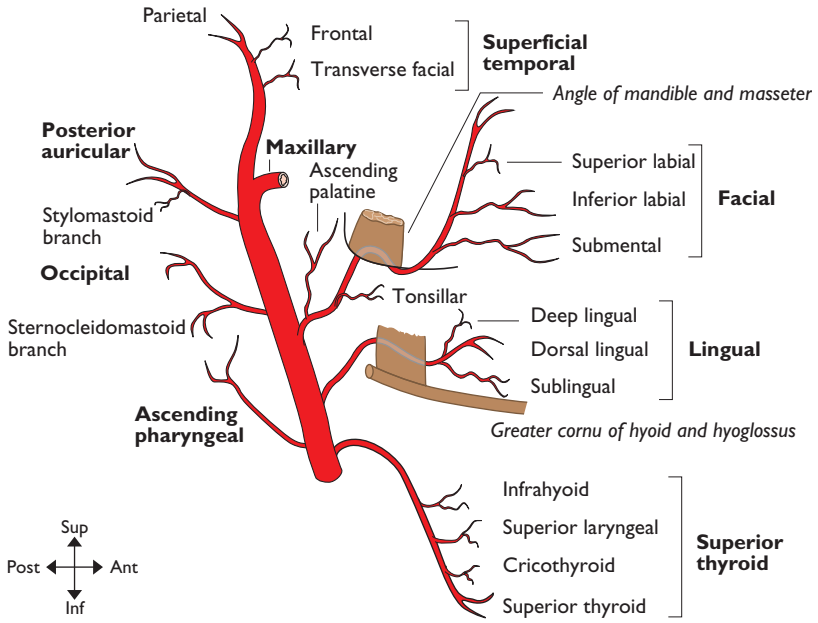
OPHTHALMIC ARTERY**From: Internal carotid art****To: Terminal brs in orbit**

It arises from the internal carotid artery as it lies medial to the anterior clinoid process and runs anteriorly through the optic canal within the optic nerve's dural sheath, lying inferolateral to the nerve. Small branches supply the proximal nerve. In the orbit the artery leaves the dural sheath and passes forwards around the lateral side of the nerve to cross anterior to it to reach the medial orbit. It then continues medially between superior oblique and medial rectus to pass out of the cone of muscles to reach the medial wall of the orbit. The artery continues forwards to terminate at the

medial orbital border deep to the superior tarsal plate as branches which leave the orbit to anastomose with branches of the facial artery.

Central retinal artery. This small, important end artery supplies the optic nerve and retina. It leaves the ophthalmic artery below the optic nerve and then, half way along the orbital part of the optic nerve, enters first the dural sheath and then the nerve itself.

(Other branches, not illustrated, (1) of ophthalmic artery are anterior meningeal and medial palpebral arteries; (2) of lacrimal artery are lateral palpebral, zygomatic and recurrent meningeal arteries; (3) of muscular is anterior ciliary artery.)



External carotid artery

EXTERNAL CAROTID ARTERY

From: Upper border of thyroid cartilage (C4)

To: Terminal brs within parotid gland post to neck of mandible

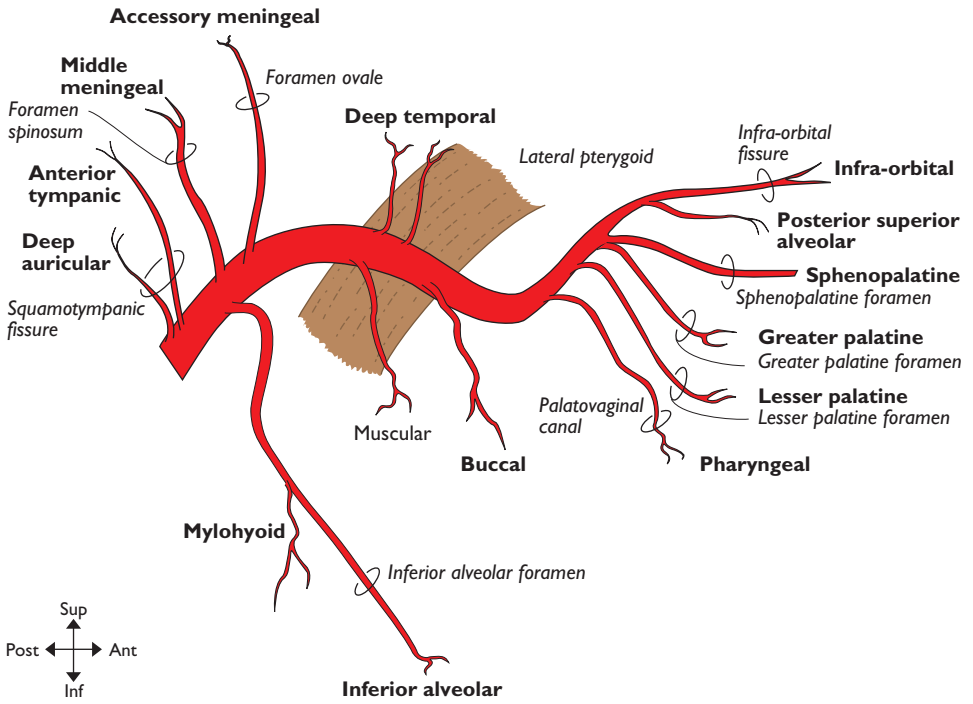
The artery arises within the carotid sheath from the bifurcation of the common carotid artery. It lies at first anteromedial to the internal carotid artery but spirals over it to come to lie lateral to it at the level of C2. Initially, it angles slightly forwards then curves backwards as it ascends to enter the parotid gland between deep and superficial lobes. During its course it is crossed by, from below upwards: the upper root of the ansa cervicalis, the hypoglossal nerve, the posterior belly of digastric, stylohyoid, the stylohyoid ligament and the facial nerve (within the parotid). Passing between it and the internal carotid artery are, from below upwards, the pharyngeal branch of the vagus (X), glossopharyngeal nerve (IX), stylopharyngeus and styloglossus. It lies on, from below upwards, pharyngeal wall, superior laryngeal branch of the vagus (X) and deep parotid lobe.

Superior thyroid artery. Arises from the anterior surface of the external carotid artery near its origin and runs inferiorly and forwards deep to omohyoid and lateral to the inferior constrictor and external laryngeal nerve to reach the upper pole of the thyroid gland.

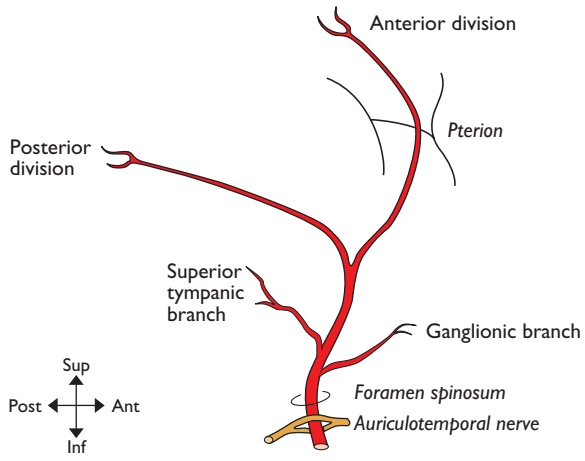
Lingual artery. Runs superiorly looping over the greater cornu of the hyoid bone and passes medially (deep) to hyoglossus then into the substance of the tongue.

Facial artery. Arises from the anteromedial surface of the external carotid artery and runs above the hyoid bone deep to digastric and passes upwards to reach the posterior surface of the submandibular gland which it grooves deeply, lying medial to the body of the mandible. Here it lies on superior constrictor, directly lateral to the palatine tonsil. It then follows a tortuous course looping at first inferiorly then upwards around the lower border of the mandible to cross the bone anterior to the insertion of masseter (where it is easily palpable). It then runs in the superficial tissues of the face towards the angle of the mouth where it turns superiorly towards the medial canthus of the eye. (Other branches, not illustrated, are glandular (to submandibular gland) and lateral nasal arteries.)

Superficial temporal artery. Runs superiorly between the deep and superficial lobes of the parotid gland, over the posterior end of the zygomatic process (where it is easily palpable) and terminates in the subcutaneous tissues of the lateral scalp.



Maxillary artery



Middle meningeal artery

MAXILLARY ARTERY**From:** External carotid within parotid gland**To:** Terminal brs in pterygopalatine fossa

It arises from the external carotid artery within the parotid gland posterior to the neck of the mandible and ends as the sphenopalatine artery. The artery is divided into three portions by its relationship posterior, in, or anterior to the lateral pterygoid muscle. The first part passes deep to the neck of the mandible between the bone and the sphenomandibular ligament and runs anteriorly lateral to the inferior alveolar nerve to reach the border of the lateral pterygoid. The second part angles anteromedially between the two heads of lateral pterygoid between anterior and posterior divisions of the mandibular nerve. The third part leaves the lateral pterygoid to enter the pterygopalatine fossa where it

terminates as branches which accompany the branches of the maxillary division of the trigeminal nerve (Vb).

Inferior alveolar artery. Passes inferolaterally posterior to the inferior alveolar nerve onto the medial surface of the ramus of the mandible which it grooves as it enters the inferior alveolar (mandibular) foramen in the mandible. It is distributed along the mandibular canal to the lower jaw and teeth. Its terminal branch appears as the mental branch through the mental foramen.

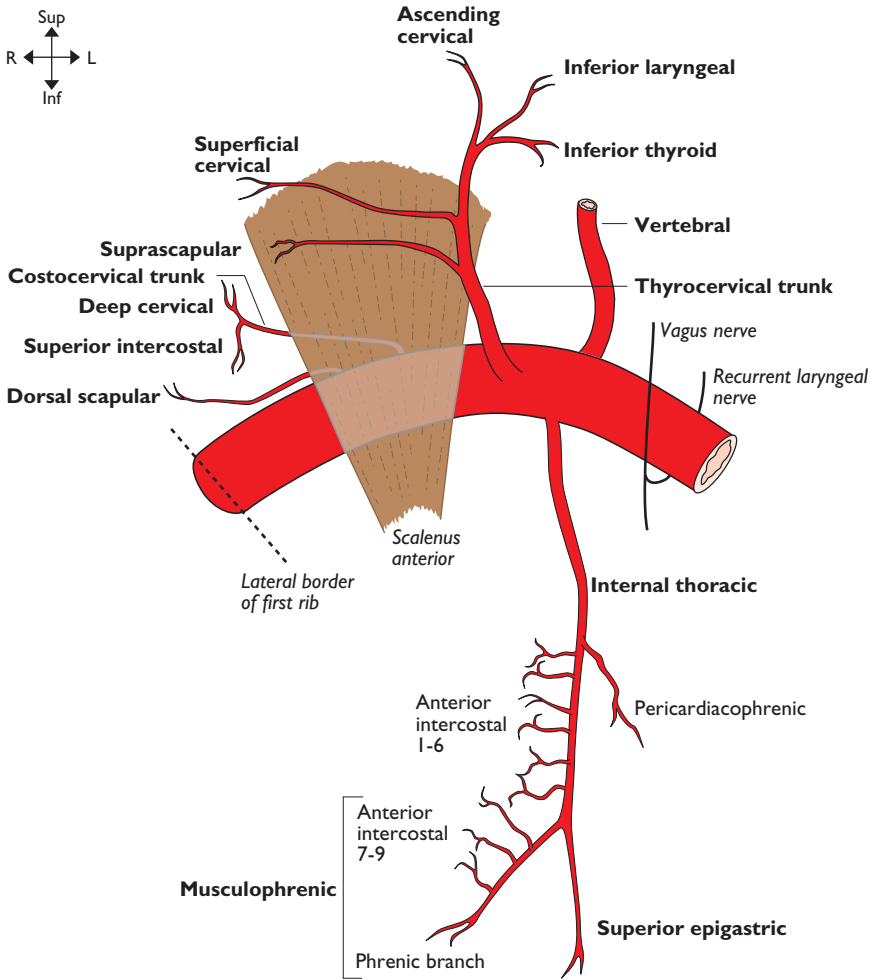
(Other branches, not illustrated, (1) of maxillary artery (third part) is artery of pterygoid canal; (2) of inferior alveolar artery are dental and mental; (3) of infraorbital artery are dental and anterior superior alveolar; (4) of posterior superior alveolar artery is dental.)

MIDDLE MENINGEAL ARTERY**From:** First part of maxillary art**To:** Terminal brs

It arises from the superomedial surface of the maxillary (first part) to run between the two rootlets of the auriculotemporal nerve as it passes vertically into the foramen spinosum in the greater wing of the sphenoid bone. After a very short course laterally over the greater wing of the sphenoid in the middle cranial fossa it divides into anterior and posterior divisions. The anterior division runs anterolaterally on the floor of the middle cranial fossa beneath the dura mater and grooves the greater wing of the sphenoid as it passes upwards to the junction of the lesser and greater wings. Here it may groove

deeply or tunnel through the bone at the apex of the greater wing. It passes across the inner aspect of the pterion onto the parietal bone. The posterior division runs almost horizontally posterolateral over the inner aspect of the squamous temporal bone onto the lower parietal bone where it gives terminal branches.

Because of the problem of extradural haemorrhage caused by damage to this artery, the surface anatomy is important. Anterior branch: 3 cm above mid point of zygomatic arch. Posterior branch: on a line vertically from the mastoid process and horizontal from the upper margin of the orbit.



Subclavian artery

Note: (1) The superficial cervical artery is named 'transverse cervical artery' if it gives origin to the dorsal scapular artery instead of the latter arising separately from the second part of the subclavian artery; (2) phrenic branch of musculophrenic artery anastomoses with inferior phrenic artery

SUBCLAVIAN ARTERY**From:** Right—brachiocephalic trunk**Left—**aortic arch**To:** Axillary art

The subclavian arteries arise as indicated above and end at the outer border of the first rib where they become the axillary arteries. They each have three parts: (1) medial (three branches); (2) behind (two branches); and (3) lateral (no branches) to scalenus anterior.

Right subclavian artery—first part. Arises from the brachiocephalic artery behind the right sternoclavicular joint, lying initially posterior to the right common carotid artery, then passing upwards and laterally to reach the medial side of scalenus anterior. Anterior to this first part are the vagus (X), its cardiac branches, sympathetic nerves, the internal jugular and vertebral veins. The ansa subclavia (sympathetic nerves) curls around the artery to lie both anterior and posterior to it. As the artery arches laterally the suprpleural membrane and the right recurrent laryngeal nerve lie inferior and posterior to it.

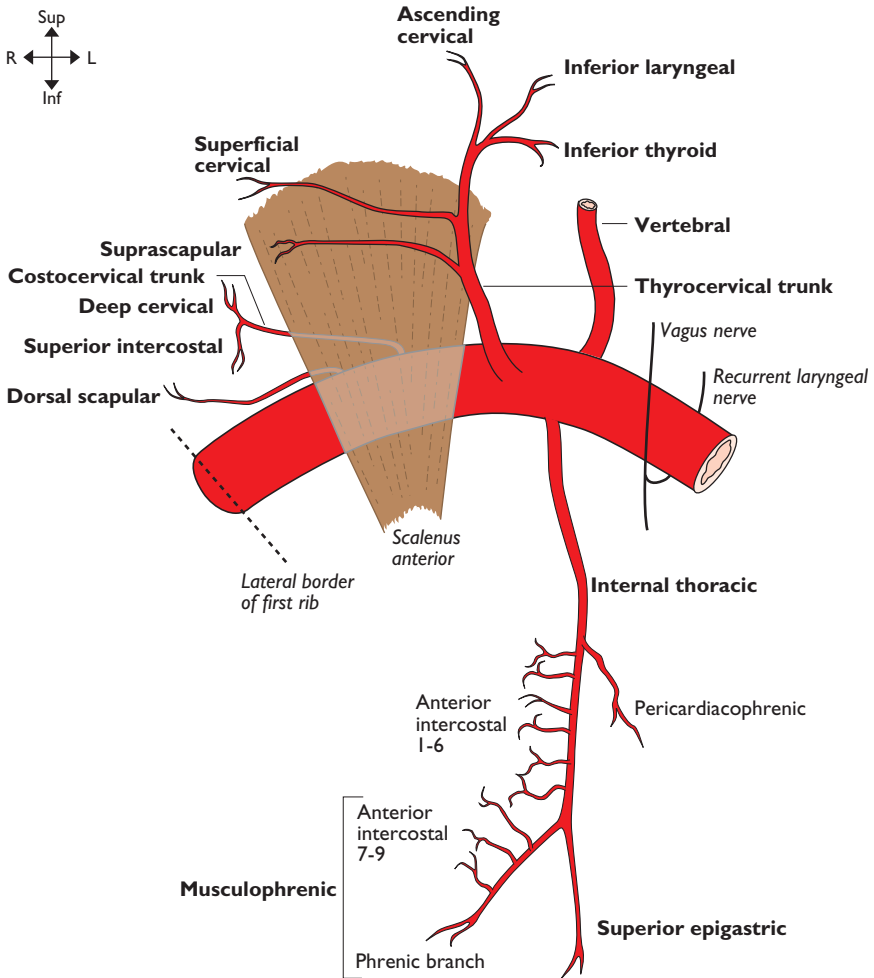
Left subclavian artery—first part. Arises from the arch of the aorta just posterior and slightly to the left of the origin of the left common carotid artery at the level of the intervertebral disc of T3/T4. It passes upwards and then, behind the left sternoclavicular joint, it arches laterally over the suprpleural membrane to the medial edge of scalenus anterior. Anterior to it in the thorax are the left common carotid artery, the left brachiocephalic vein, the left vagus and its cardiac branches and the left phrenic nerve. Posterior to it lie the left side of the oesophagus, the thoracic duct and longus colli. Medial to it is the trachea, the left recurrent laryngeal nerve and, more superiorly, the thoracic duct. In the neck it is crossed anteriorly by the left phrenic nerve and the thoracic duct.

Subclavian artery—second part. Lies posterior to scalenus anterior and anterior to scalenus medius. Anterior to scalenus anterior are the phrenic nerve and, slightly inferior, the subclavian vein. Postero-inferior are the suprpleural membrane and the lower trunk of the brachial plexus. Superior to it are the upper and middle trunks of the brachial plexus.

Subclavian artery—third part. Begins at the lateral margin of scalenus anterior and extends to the outer (lateral) margin of the first rib where it becomes the axillary artery. Anterior to it is the external jugular vein and its tributaries. Antero-inferior is the subclavian vein. Postero-inferior is the lower trunk of the brachial plexus and the first rib. Posterosuperior are the upper and middle trunks of the brachial plexus.

Vertebral artery (see also internal carotid, vertebrobasilar system & circle of Willis, pp. 8–9). Arises from the posterosuperior aspect of the first part of the subclavian artery and ends where the arteries from the two sides join to form the basilar artery at the lower pons. It angles posteriorly between the medial border of scalenus anterior and the lateral border of longus colli in the apex of the pyramidal space before entering the foramen in the transverse process of C6 behind its anterior tubercle (carotid tubercle of Chassaignac). Lying anterior to this first part are the common carotid artery and the vertebral vein and, more medially, the inferior thyroid artery and middle cervical ganglion. On the left the thoracic duct crosses it anteriorly. Posterior to it are the anterior primary rami of C7 and C8 nerves and more medially the inferior cervical (stellate) ganglion. The second part of the artery ascends within the foramina of the transverse processes of C6 to C1, accompanied by sympathetic nerves and vertebral veins. It passes out posteriorly behind the lateral mass of the atlas before

continued



Subclavian artery

Note: (1) The superficial cervical artery is named 'transverse cervical artery' if it gives origin to the dorsal scapular artery instead of the latter arising separately from the second part of the subclavian artery; (2) phrenic branch of musculophrenic artery anastomoses with inferior phrenic artery

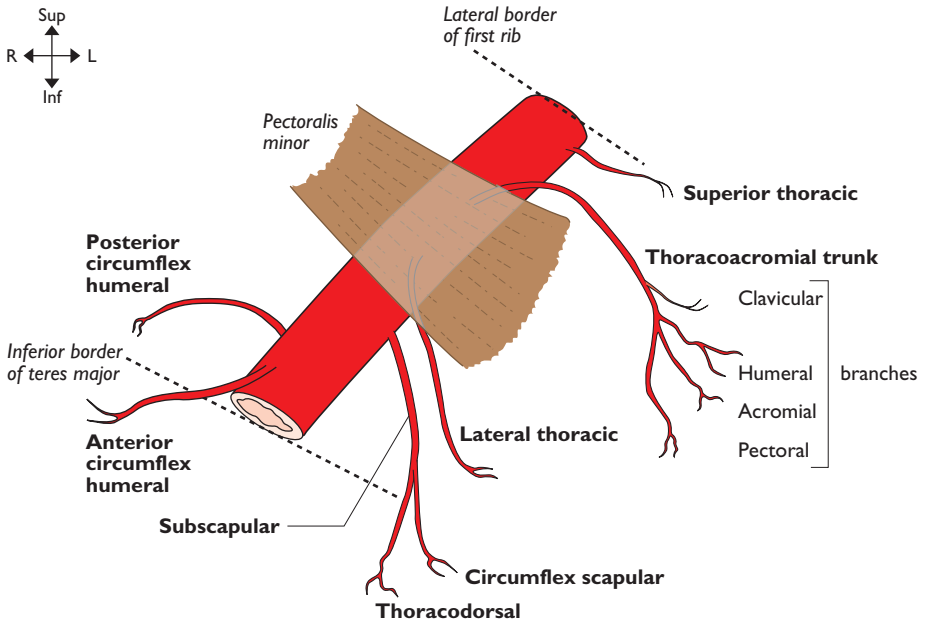
turning medially over its posterior arch. It then turns anteriorly to pierce the atlanto-occipital membrane lateral to the cervicomedullary junction. It pierces the dura and arachnoid to ascend superomedially around the anterior aspect of the medulla where it joins the artery from the opposite side at the lower border of the pons to form the basilar artery. (Other branches, not illustrated, are spinal, meningeal and muscular.)

Internal thoracic artery. Arises from the anterior aspect of the first part of the subclavian artery and passes inferiorly behind the brachiocephalic vein and the phrenic nerve to reach the dome of the pleura. It then angles medially to lie posterior to the upper six costal cartilages, between the internal intercostal and transversus thoracis muscles. It terminates at the 6th intercostal space to give the superior

epigastric and musculophrenic arteries. (Other branches, not illustrated, are mediastinal, thymic, sternal and perforating (mammary).)

Inferior thyroid artery. Ascends along the medial edge of scalenus anterior. Just below the anterior tubercle of C6 it turns medially to reach the lower thyroid gland, passing between vertebral artery and vein (posteriorly) and carotid sheath and sympathetic chain (anteriorly). Its terminal branches are often amongst the recurrent laryngeal nerve. (Other branches of inferior thyroid artery, not illustrated, are glandular, pharyngeal, oesophageal and tracheal.)

Superior intercostal artery. Passes inferiorly, anterior to the necks of the first two ribs to provide the posterior intercostal arteries for the first two intercostal spaces.



Axillary artery

AXILLARY ARTERY**From:** Subclavian art**To:** Brachial art

This is the continuation of the subclavian artery. It commences at the lateral border of the 1st rib and ends at the inferior border of teres major to become the brachial artery. It is divided into three parts by pectoralis minor. It is invested in a fascial sheath arising from the prevertebral fascia.

First part is medial to the upper border of pectoralis minor and has one branch. Anterior to it is the clavipectoral fascia, subclavius and the lateral pectoral nerve. The axillary vein is medial whilst posterior to it are the upper part of serratus anterior, the long thoracic nerve, the medial pectoral nerve and the medial cord of the brachial plexus. Lateral to it are the lateral and posterior cords of the brachial plexus.

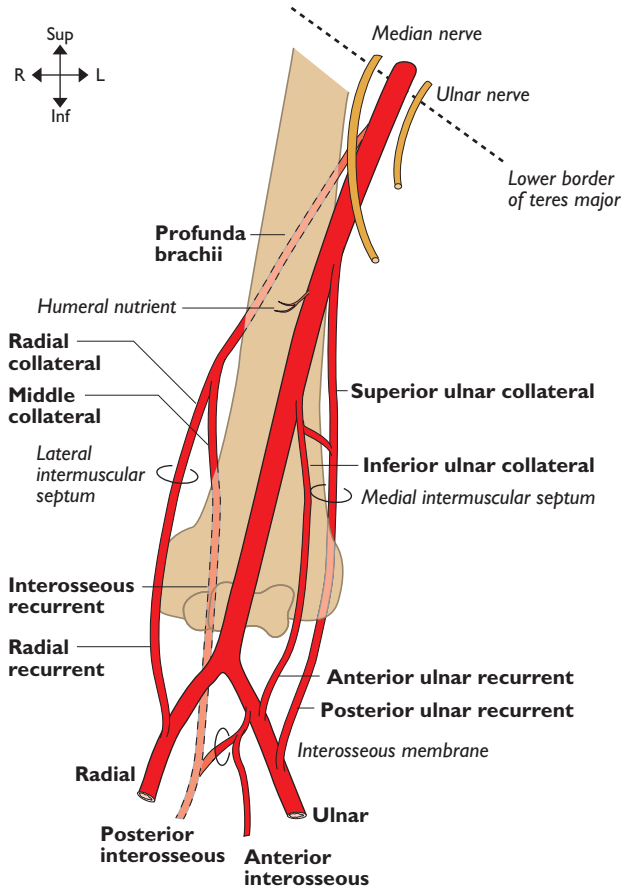
Second part has pectoralis minor lying anterior to it and has two branches. Medial to it is the axillary vein and medial cord of

the brachial plexus. Posterior to it are the posterior cord and subscapularis whilst lateral to it is the lateral cord of the brachial plexus.

Third part extends from the lower border of pectoralis minor to the inferior border of teres major and has three branches. Anterior to it are pectoralis major, the clavipectoral fascia and the median nerve. Medial to it lie the axillary vein and the ulnar nerve. Posterior to it are the radial nerve, teres major, subscapularis and the tendon of latissimus dorsi. On its lateral side lie the musculocutaneous nerve, lateral root (head) of the median nerve, the tendon of biceps in the bicipital groove and coracobrachialis.

Posterior circumflex humeral artery. Passes posteriorly through the quadrangular space with the axillary nerve to supply shoulder joint and surrounding muscles.

Note. Lateral thoracic artery and pectoral branches of the thoraco-acromial trunk are important supply vessels for the breast.



Brachial artery

BRACHIAL ARTERY

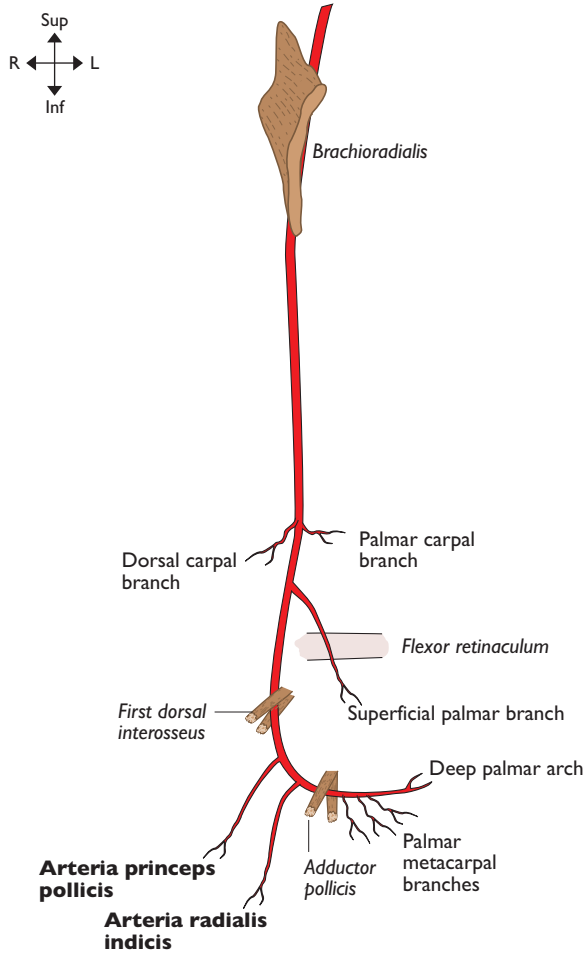
From: Axillary art

To: Radial & ulnar arts

This is the continuation of the axillary artery beginning at the lower margin of the teres major and ending in the cubital fossa at the level of the neck of the radius as the radial and ulnar arteries. At first it lies medial to the humerus then it spirals around to lie anterior to it. It is superficial throughout its course and accompanied by venae comitantes. It is crossed from lateral to medial by the median nerve in the mid arm and by the bicipital aponeurosis in the cubital fossa. Medial to it is the ulnar nerve in the upper

arm and, distally, the median nerve. Lateral to it high up are the median and musculo-cutaneous nerves. Coracobrachialis, biceps and its tendon also lie on its lateral side. The artery lies first on the long and then the medial head of triceps, then brachialis in the lower third of the arm.

Arteria profunda brachii. Leaves the posteromedial aspect of the brachial artery just below teres major and passes posteriorly between the long and medial heads of triceps with the radial nerve and into the radial groove before breaking up into its terminal branches.

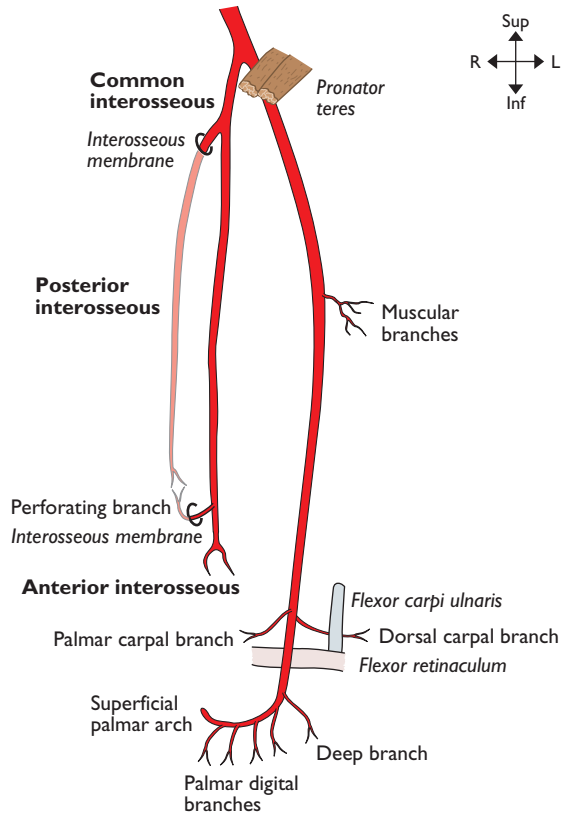


Radial artery

RADIAL ARTERY**From: Brachial art in midline of cubital fossa****To: Deep palmar arch in hand**

The radial artery arises at the terminal bifurcation of the brachial artery in the cubital fossa at the level of the neck of the radius. It crosses anterior to the biceps tendon to lie initially on supinator. It then passes down the radial side of the forearm lying consecutively on pronator teres, the radial head of flexor digitorum superficialis, flexor pollicis longus and the insertion of pronator quadratus before passing onto the lower end of the radius where its pulse is palpable as it lies lateral to the tendon of flexor carpi radialis. It thus lies deep to brachioradialis and, to a lesser extent, flexor carpi radialis. The superficial branch of the radial nerve lies lateral to it in the forearm. It gives off a palmar carpal branch which contributes to the palmar carpal arch. It then gives off a superficial palmar branch (palmar cutaneous branch) which supplies the thenar muscles before anastomosing with the superficial palmar arch. The radial artery

then passes beneath the tendons of abductor pollicis longus and extensor pollicis brevis to enter the anatomical snuff box. It passes across the snuff box on the scaphoid and trapezium and under the tendon of extensor pollicis longus. It gives off a dorsal carpal branch to the dorsal carpal arch which in turn supplies the wrist joint, the dorsal aspects of the metacarpals and the dorsal digital arteries. The radial artery then passes down between the two heads of the first dorsal interosseus and, before it enters the palm of the hand, it gives off two named vessels—arteria princeps pollicis (first palmar metacarpal artery) and arteria radialis indicis. The continuation of the radial artery then passes between the two heads of adductor pollicis to become the deep palmar arch which lies 1 cm proximal to the superficial palmar arch (ulnar artery). It supplies the palmar metacarpals, gives off a recurrent branch to the palmar carpal arch and three perforating branches which anastomose with the dorsal metacarpal arteries.



Ulnar artery

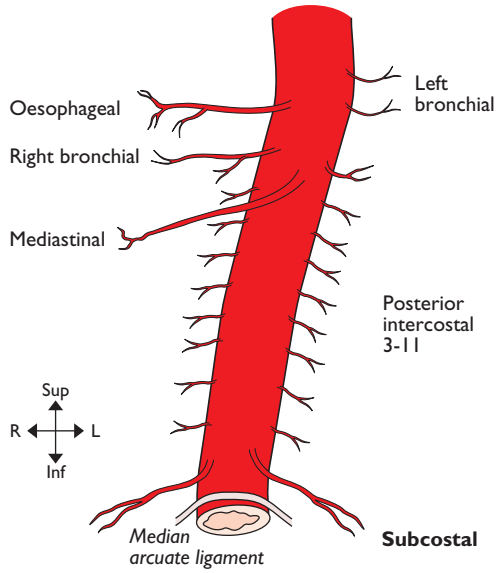
ULNAR ARTERY**From:** Brachial art**To:** Superficial palmar arch in hand

The artery arises as the terminal bifurcation of the brachial artery in the cubital fossa at the level of the neck of the radius. It leaves the fossa deep to the deep head of pronator teres and deep to the fibrous arch of flexor digitorum superficialis just lateral to the median nerve to cross beneath the nerve before running down the ulnar side of the forearm. It lies on flexor digitorum profundus with the ulnar nerve on its medial side. It lies lateral to flexor carpi ulnaris before passing superficial to the flexor retinaculum. The dorsal and palmar carpal arteries contribute, with similarly named arteries from the radial artery, to the dorsal and palmar carpal arches. The ulnar artery then gives off a deep branch to the deep palmar arch before forming the superficial palmar arch at the level of the distal border of the extended thumb. The superficial arch supplies the hypothenar eminence and gives off the palmar digital arteries. At the level of pronator teres the ulnar artery gives off the common interosseous artery which divides

into anterior and posterior interosseous arteries.

Anterior interosseous artery. Descends on the anterior surface of the interosseous membrane together with the anterior interosseous branch of the median nerve lying between flexor digitorum profundus medially and flexor pollicis longus laterally. Branches perforate the membrane to supply the extensor muscles. Above pronator quadratus it gives off a small branch which descends deep to the muscle to join the palmar carpal arch, then the anterior interosseous artery itself passes posteriorly through the membrane to anastomose with the posterior interosseous artery which descends to join the dorsal carpal arch.

Posterior interosseous artery. Passes posteriorly above the interosseous membrane and then runs between supinator superficially and abductor pollicis longus deeply with the deep branch of the radial nerve (posterior interosseous nerve) to descend to supply the extensor muscles of the forearm. It anastomoses with the distal branches of the anterior interosseous artery and dorsal carpal arch.

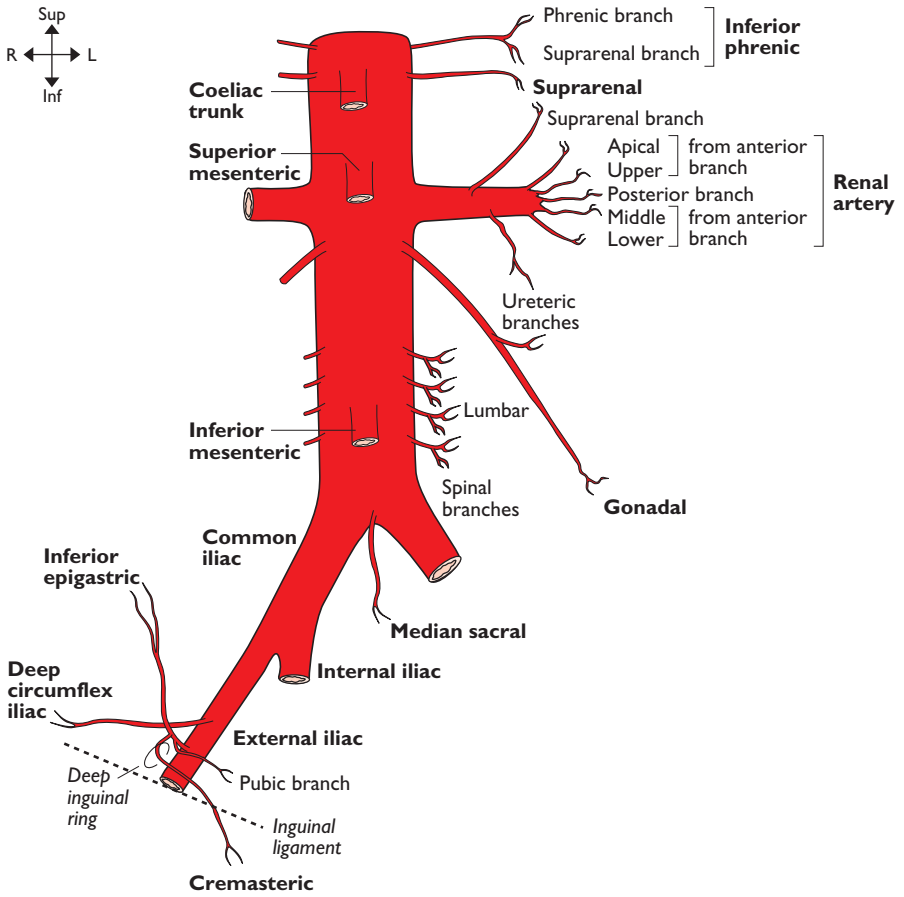


Thoracic (descending) aorta

THORACIC (DESCENDING) AORTA**From: Arch of aorta****To: Abdominal aorta**

This arises as the continuation of the arch of the aorta commencing to the left of the body of T4 and ends as it passes into the abdomen at T12. It grooves the left side of the bodies of T4–T6 vertebrae then it inclines medially to lie in the midline over the lower thoracic vertebrae. It passes out of the thorax at T12 posterior to the median arcuate ligament of the diaphragm to become the abdominal aorta. Lying anterior to it from above down

are the hilum of the left lung (particularly the left main bronchus), pericardium, left atrium, oesophagus and diaphragm. Posterior lie the necks of the ribs of T5–T6 and the sympathetic chain at that level, the vertebral bodies and hemiazygos veins. To its right lie the right pleura and lung and thoracic duct. The oesophagus and its surrounding plexus of nerves is initially to its right but lower down it crosses the aorta to lie anterior then slightly to the left. To its left are the left pleura and lung. (Other branch, not illustrated, is pericardial.)



Abdominal aorta & external iliac artery

ABDOMINAL AORTA**From:** Thoracic aorta**To:** Common iliac arts

This main artery arises as the continuation of the thoracic aorta as it passes, in the midline, posterior to the median arcuate ligament of the diaphragm at T12 and it ends slightly to the left of the midline at L4 where it terminates as the left and right common iliac arteries. Anterior to it, from above downwards, are the coeliac trunk and its branches, the coeliac plexus, lesser sac, superior mesenteric artery, left renal vein, body of pancreas, commencement of each gonadal artery, fourth part of the duodenum, posterior parietal peritoneum, attachment of the mesentery and inferior mesenteric artery. Posterior to it are the lumbar arteries and left lumbar veins, anterior longitudinal ligament and vertebral bodies with their intervertebral discs. To its right are the cisterna chyli, thoracic duct, azygos vein, right crus of diaphragm and inferior vena cava. To its left are the left crus of diaphragm, left coeliac ganglion, the duodenojejunal flexure (upper border of L2), sympathetic trunk and inferior mesenteric vessels. On both sides the phrenic, suprarenal and renal vessels are lateral whilst distal to the bifurcation of the abdominal aorta is the median sacral artery.

Common iliac arteries. These commence at the bifurcation of the abdominal aorta just to the left of the midline at L4 and pass inferolaterally to the level between L5 and S1 vertebrae where they bifurcate anterior to the sacro-iliac joint to give the external and

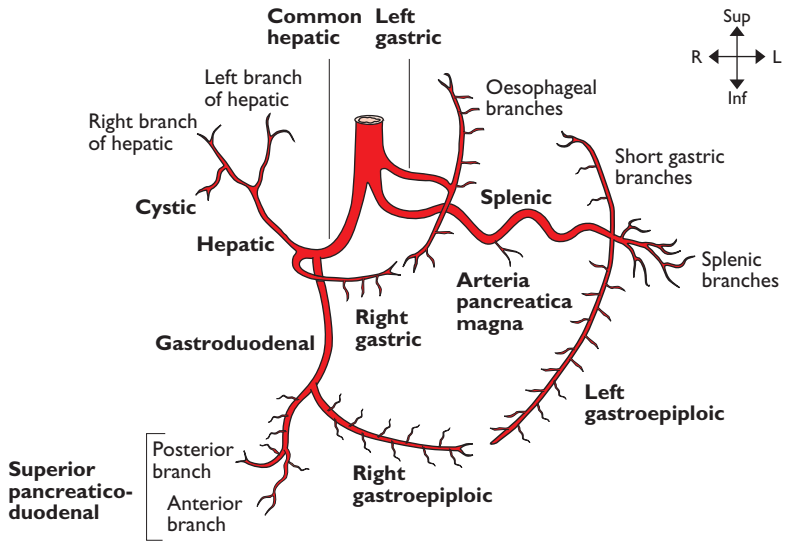
internal iliac arteries. Anterior to each vessel are sympathetic contributions to the superior hypogastric plexus, the ureter (near the terminal bifurcation of the vessel), peritoneum and small bowel. In addition on the left side the superior rectal artery lies anterior. Posterior to each vessel are the sympathetic trunk, obturator nerve, lumbosacral trunk, iliolumbar artery and the bodies of L4 and L5 with the disc between them. In addition posteriorly on the right side are the terminal portions of the common iliac veins and the commencement of the inferior vena cava. The left common iliac vein lies posteromedial to the left common iliac artery. Psoas major lies lateral to each vessel.

Gonadal artery. Descends passing obliquely inferiorly on the posterior abdominal wall to the level of the external iliac artery. The testicular arteries pass around the lower border of the false pelvis to enter the inguinal canal through the deep ring to form part of the spermatic cord. The ovarian vessels descend over the external iliac vessels into the infundibulopelvic fold to supply the ovary via the broad ligament. The common relations of the arteries in both sexes are: left, posterior—psoas, genitofemoral nerve, ureter and external iliac artery; left, anterior—inferior mesenteric vein, left colic artery and sigmoid mesentery; right, posterior—inferior vena cava, psoas, genitofemoral nerve, ureter and external iliac artery; right, anterior—third part of the duodenum, right colic artery and ileal mesentery.

EXTERNAL ILIAC ARTERY**From:** Common iliac art**To:** Femoral art

The external iliac artery descends laterally from the common iliac artery to pass under the inguinal ligament at the mid inguinal point (half way between the anterior superior iliac spine and symphysis pubis) where it becomes the femoral artery.

Posterior and lateral to it is the medial border of psoas major whilst the femoral vein comes to lie medially. Anteromedially it is covered by peritoneum on which lies small bowel with sigmoid colon additionally on the left. It is crossed at its origin by the ureter and then by the gonadal vessels, genital branch of the genitofemoral nerve, deep circumflex iliac vein and vas deferens or round ligament.



Coeliac trunk

COELIAC TRUNK

From: Abdominal aorta at lower border of T12

To: Terminal brs—left gastric, splenic & common hepatic arts

The coeliac trunk (axis) arises from the anterior aspect of the abdominal aorta at the level of the lower border of T12 and after 1 cm divides into its three terminal branches.

Left gastric artery. Passes superolaterally on the posterior wall of the lesser sac to reach the apex of this structure at the cardio-oesophageal junction where it divides into oesophageal branches to supply the lower third of the oesophagus through the oesophageal opening in the diaphragm. Its terminal gastric branches run inferiorly along the upper portion of the lesser curve of the stomach to anastomose with the right gastric artery.

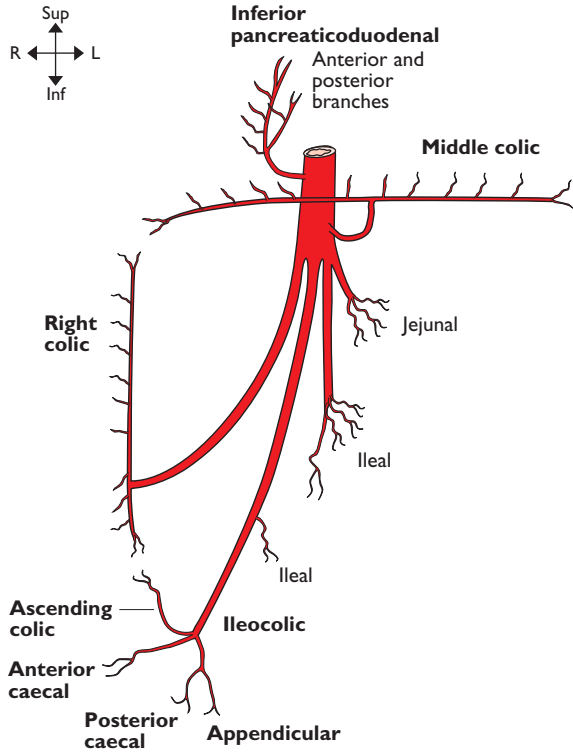
Splenic artery. Passes laterally to the left, angled slightly superiorly, running in the posterior wall of the lesser sac. Its course is markedly tortuous as it runs along the superior border of the pancreas, passing anterior to the left crus of the diaphragm, the upper pole of the left kidney and the left suprarenal gland before entering the

lienorenal ligament to reach the splenic hilum.

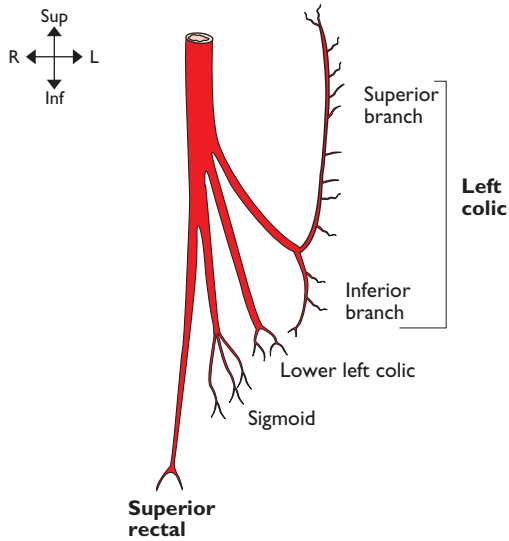
Common hepatic artery. Runs inferolaterally to the right in the posterior wall of the lesser sac towards the first part of the duodenum where it gives off first the gastroduodenal and then right gastric arteries. It then curves anteriorly as the hepatic artery to pass into the peritoneal reflection which forms the inferior margin of the opening of the lesser sac. It approaches the portal vein from its left side and then comes to lie anterior to it, with the bile duct on its right, as it ascends in the free border of the lesser omentum (anterior margin of the foramen of Winslow or epiploic foramen) before terminating at the porta hepatis as the right and left hepatic branches.

Gastroduodenal artery. Descends directly behind the first part of the duodenum to the left of the bile duct and divides at the upper border of the pancreas into terminal branches.

Right gastric artery. Arises from the hepatic artery as it enters the lesser omentum and passes along the lesser curve of the stomach to anastomose with the left gastric artery.



Superior mesenteric artery



Inferior mesenteric artery

SUPERIOR MESENTERIC ARTERY**From:** Abdominal aorta**To:** Terminal brs

The superior mesenteric artery arises from the anterior surface of the abdominal aorta at the level of L1. It passes inferiorly over the left renal vein with the splenic vein and body of pancreas anterior to it. It next lies on the uncinate process of the pancreas and the junction of the third and fourth parts of the duodenum from where it passes obliquely and to the right into the mesentery of the small bowel before giving off its terminal branches. The superior mesenteric vein is on its right whilst posterior to the terminal branches are the inferior vena cava, the right ureter and psoas major. The superior mesenteric plexus of nerves surrounds the artery. It supplies bowel from the mid second part of the duodenum, jejunum, ileum, ascending and right two-thirds of transverse colon.

Inferior pancreaticoduodenal artery. Leaves the superior mesenteric artery as it begins to cross the duodenum and divides into an anterior and posterior branch. The anterior branch passes to the right to anastomose with the anterior superior pancreaticoduodenal artery anterior to the head of the pancreas. The posterior branch passes also to the right but posterior to the head of the pancreas to anastomose with the posterior superior pancreaticoduodenal artery.

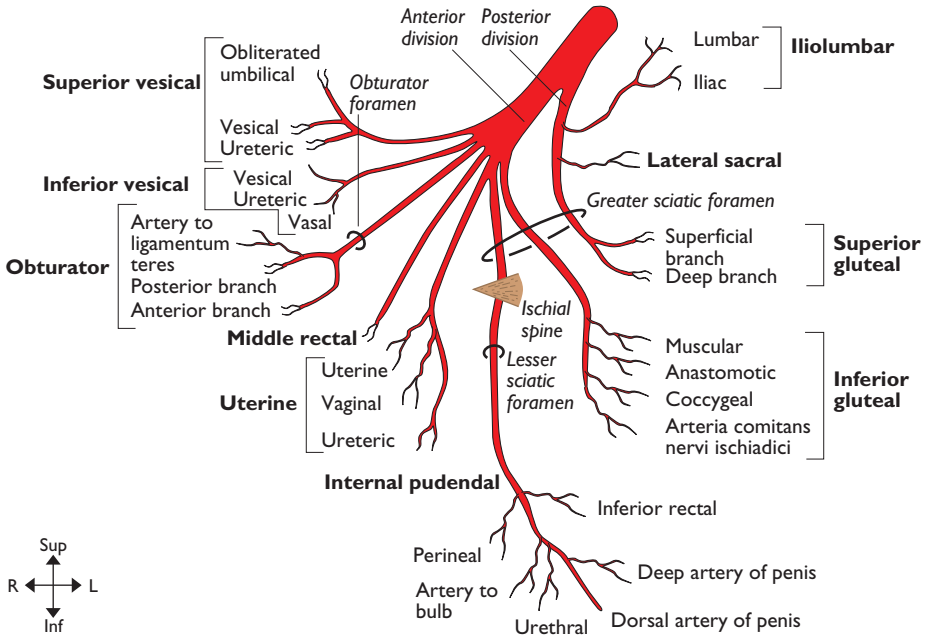
Middle colic artery. Note that this artery arises early from the superior mesenteric artery to supply the transverse colon. This is logical as the right colic would otherwise need to be excessively long.

Ileocolic artery. Passes obliquely inferiorly to the right in the root of the mesentery where it passes anterior to the right ureter and right gonadal vessels to reach the caecum where it divides into its terminal branches.

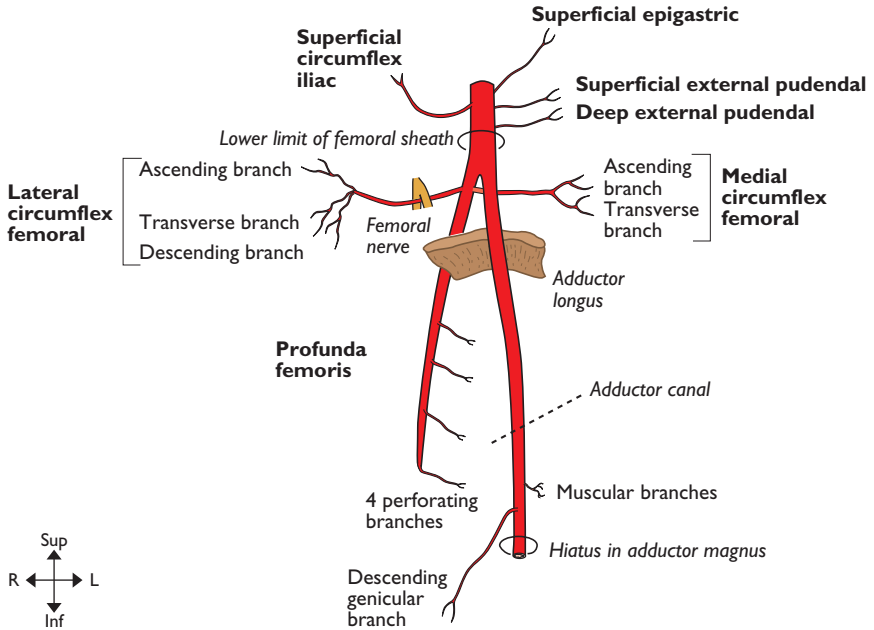
INFERIOR MESENTERIC ARTERY**From:** Abdominal aorta**To:** Terminal brs

This artery arises from the anterior surface of the abdominal aorta at the level of L3 posterior to the third and fourth part of the duodenum. It passes inferiorly and to the left

crossing the left common iliac artery medial to the left ureter. The inferior mesenteric vein lies on its left (lateral) side. It divides into its terminal branches in the descending mesocolon. It supplies the left third of the transverse colon, the descending and sigmoid colon and the rectum to the dentate line of the anus.



Internal iliac artery



Femoral artery

INTERNAL ILIAC ARTERY**From:** Common iliac art**To:** Terminal brs

The artery commences at the level of the disc between L5 and S1 and passes posteriorly into the pelvis for 4 cm before forming anterior and posterior divisions which break up into their terminal branches. Anterior lie the ureter and fallopian tube and ovary in the female. Posterior are the internal iliac vein, lumbosacral trunk and sacro-iliac joint. On the lateral side are the external iliac artery and vein, obturator nerve and psoas major. The parietal peritoneum and small bowel lie medially.

Internal pudendal artery. Arises from the anterior division of the internal iliac artery and descends on the lateral wall of the pelvis towards the greater sciatic foramen. It leaves

the pelvis via this foramen, inferior to piriformis, before passing over the tip of the ischial spine to enter the ischio-anal fossa via the lesser sciatic foramen. It runs on the lateral wall of the ischio-anal fossa on obturator internus in the pudendal (Alcock's) canal. It passes into the deep perineal pouch where it gives off its terminal branches. (Other branches of the perineal branch, not illustrated, are transverse perineal and posterior scrotal.)

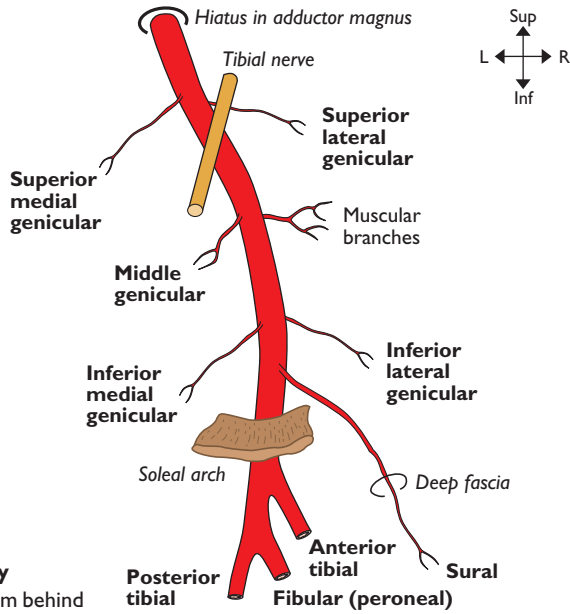
Note: In the female the vaginal artery is equivalent to the inferior vesical artery in the male, and the uterine artery is equivalent to the middle rectal artery. The round ligament is supplied by the uterine artery whilst the vas deferens is usually supplied by the inferior vesical or less often by the superior vesical artery.

FEMORAL ARTERY**From:** External iliac art**To:** Popliteal art

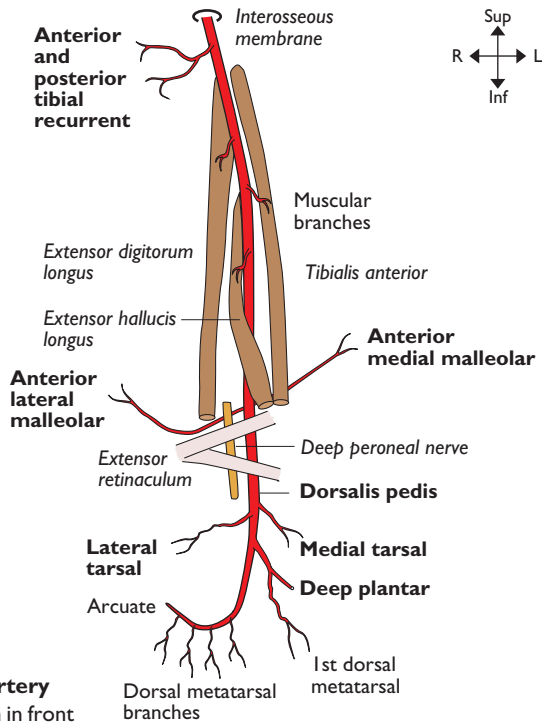
This is the continuation of the external iliac artery and commences posterior to the inguinal ligament at the mid-inguinal point (half way between the anterior superior iliac spine and the symphysis pubis). It ends as it passes through the adductor hiatus in adductor magnus to become the popliteal artery. It emerges from under the inguinal ligament with the femoral vein medial to it, both within the femoral sheath. Lateral to it and outside the femoral sheath is the femoral nerve. It lies on the tendon of psoas major and is separated from pectineus and adductor longus by the femoral vein which comes to lie progressively more posterior to

the artery within the femoral triangle. As the femoral artery enters the adductor canal it lies on adductor longus then adductor magnus. It is covered initially only by deep fascia then by sartorius; the saphenous nerve passes anteriorly from lateral to medial. Anterolateral to the artery is vastus medialis.

Profunda femoris is the main branch of the femoral artery which is given off posterolaterally just below the femoral sheath 3.5 cm below the inguinal ligament. It runs posteriorly between pectineus and adductor longus to pass into the deep thigh where it provides the deep structures and the posterior and medial compartments with their main arterial supply. Perforating and descending branches anastomose with the genicular branches of the popliteal artery.



Popliteal artery
Note: viewed from behind



Anterior tibial artery
Note: viewed from in front

POPLITEAL ARTERY**From: Femoral art****To: Ant & post tibial arts**

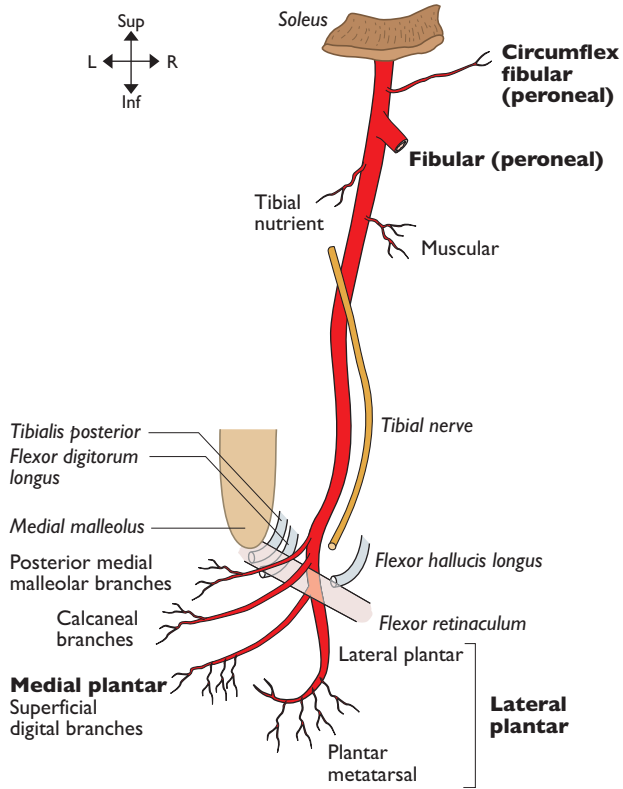
This artery commences as the continuation of the femoral artery as the latter passes through the hiatus in adductor magnus and ends as it passes under the fibrous arch of soleus where it immediately divides into anterior and posterior tibial arteries. The popliteal artery extends from a hand's breadth above the knee and to the same

distance below it. It enters the popliteal fossa medial to the femur and becomes the deepest structure, lying with only fat between it and the popliteal surface of the femur. Lower down it lies on the capsule of the knee joint and then on popliteus. Biceps femoris is lateral to it and semimembranosus medial. Lower down it lies between the two heads of gastrocnemius. It is crossed laterally to medially by the tibial nerve and the popliteal vein with the vein always between the artery and nerve.

ANTERIOR TIBIAL ARTERY**From: Popliteal art****To: Dorsalis pedis art**

This artery commences at the bifurcation of the popliteal artery just under the fibrous arch of soleus, at the distal border of popliteus. It supplies the structures in the extensor compartment of the lower leg. It passes anteriorly between the heads of tibialis posterior to pass above the upper border of the interosseous membrane, medial to the neck of the fibula accompanied by its venae comitantes. It descends on the interosseous membrane and crosses the lower tibia at the ankle joint, mid way

between the malleoli and there becomes the dorsalis pedis artery. Initially it lies between tibialis anterior (medially) and extensor digitorum longus (laterally), then between tibialis anterior and extensor hallucis longus. At the ankle it is crossed anteriorly by the extensor retinacula and also from lateral to medial by the tendon of extensor hallucis longus. The deep fibular (peroneal) nerve is initially lateral to the artery high up in the extensor compartment but passes anterior to it half way down the leg, becoming lateral to it again under the extensor retinaculum. The anterior tibial veins run in close association with the artery throughout.

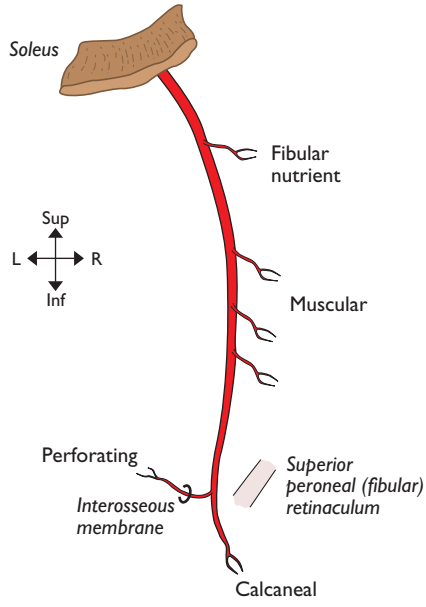


Posterior tibial artery
Note: viewed from behind

POSTERIOR TIBIAL ARTERY**From:** Popliteal art**To:** Med & lat plantar arts

This artery arises at the bifurcation of the popliteal artery just under the fibrous arch of soleus, at the lower border of popliteus, and ends by bifurcating into the medial and lateral plantar arteries deep to abductor hallucis. It supplies structures in the posterior compartment of the lower leg. It is accompanied by venae comitantes and lies

from above downwards on tibialis posterior, flexor digitorum longus, the tibia and the ankle joint. It lies deep to gastrocnemius, soleus, the flexor retinaculum and abductor hallucis. Posterior to the medial malleolus it lies between the tendon of flexor digitorum longus and the tibial nerve which crosses posterior to the artery mid way down the calf from the medial side to become postero-lateral. (Other branch, not illustrated, is a communicating branch to the fibular (peroneal) artery.)

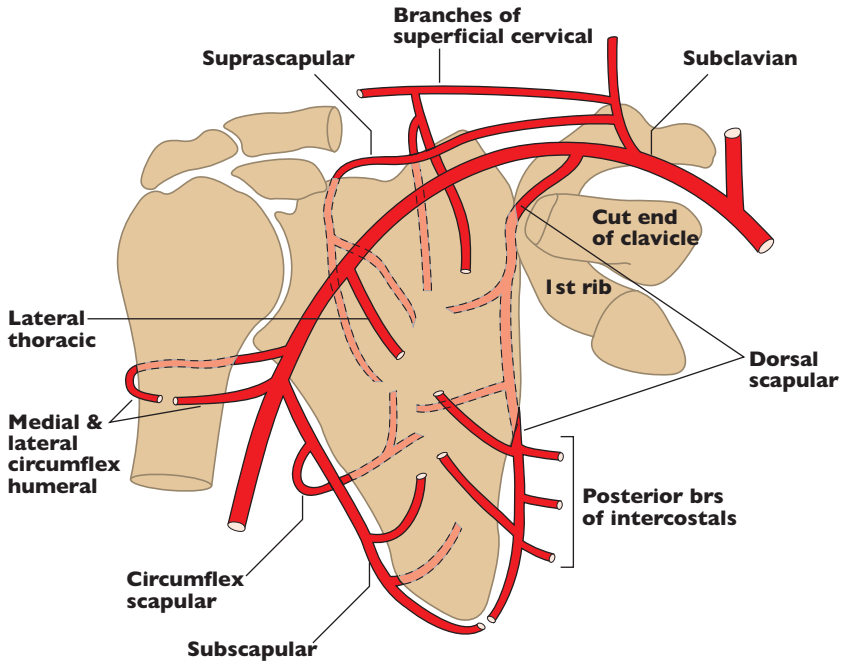


Fibular (peroneal) artery

FIBULAR (PERONEAL) ARTERY**From:** Post tibial art**To:** Terminal brs

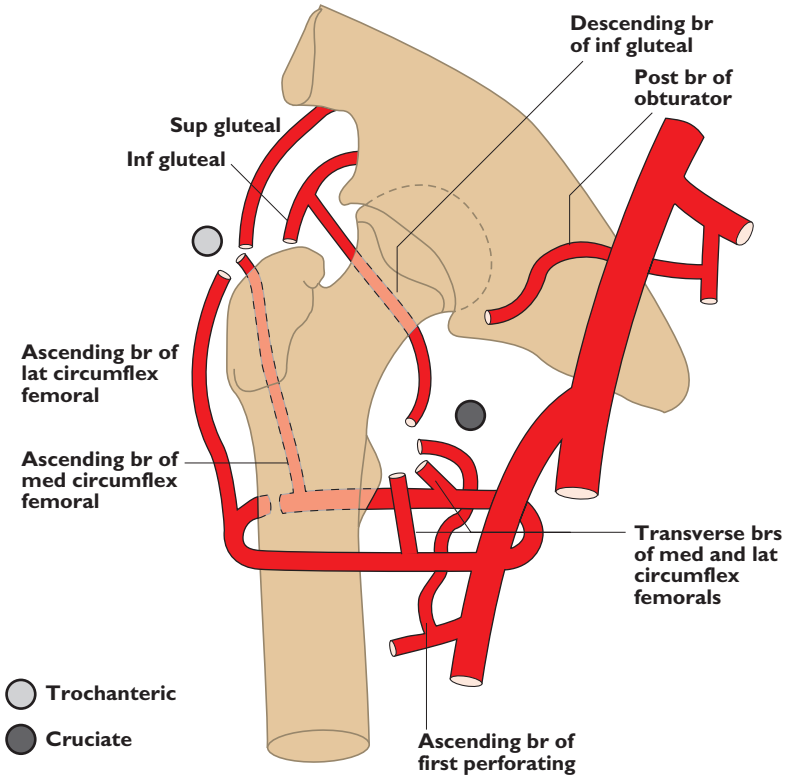
This is a branch of the posterior tibial artery arising 2.5cm below its origin under soleus. It supplies structures in the lateral compartment of the lower leg. Due to the proximity of origin of the three terminal branches of the popliteal artery this point of origin is commonly referred to as the 'popliteal trifurcation'. It passes inferolaterally to reach and run along the

medial crest of the fibula between tibialis posterior and flexor hallucis longus to divide into its terminal branches at the level of the inferior tibiofibular joint and the superior fibular (peroneal) retinaculum. Thus, although it supplies the fibular (peroneal) compartment by branches that pass laterally, the main fibular (peroneal) artery itself remains in the posterior compartment. Above, it is covered by soleus and deep fascia whilst in the lower leg flexor hallucis longus crosses it from lateral to medial.



Arterial anastomoses around scapula

Note: The superficial cervical artery is named "transverse cervical artery" if it gives origin to the dorsal scapular artery instead of the latter arising separately from the second part of the subclavian artery



Arterial anastomoses around hip

