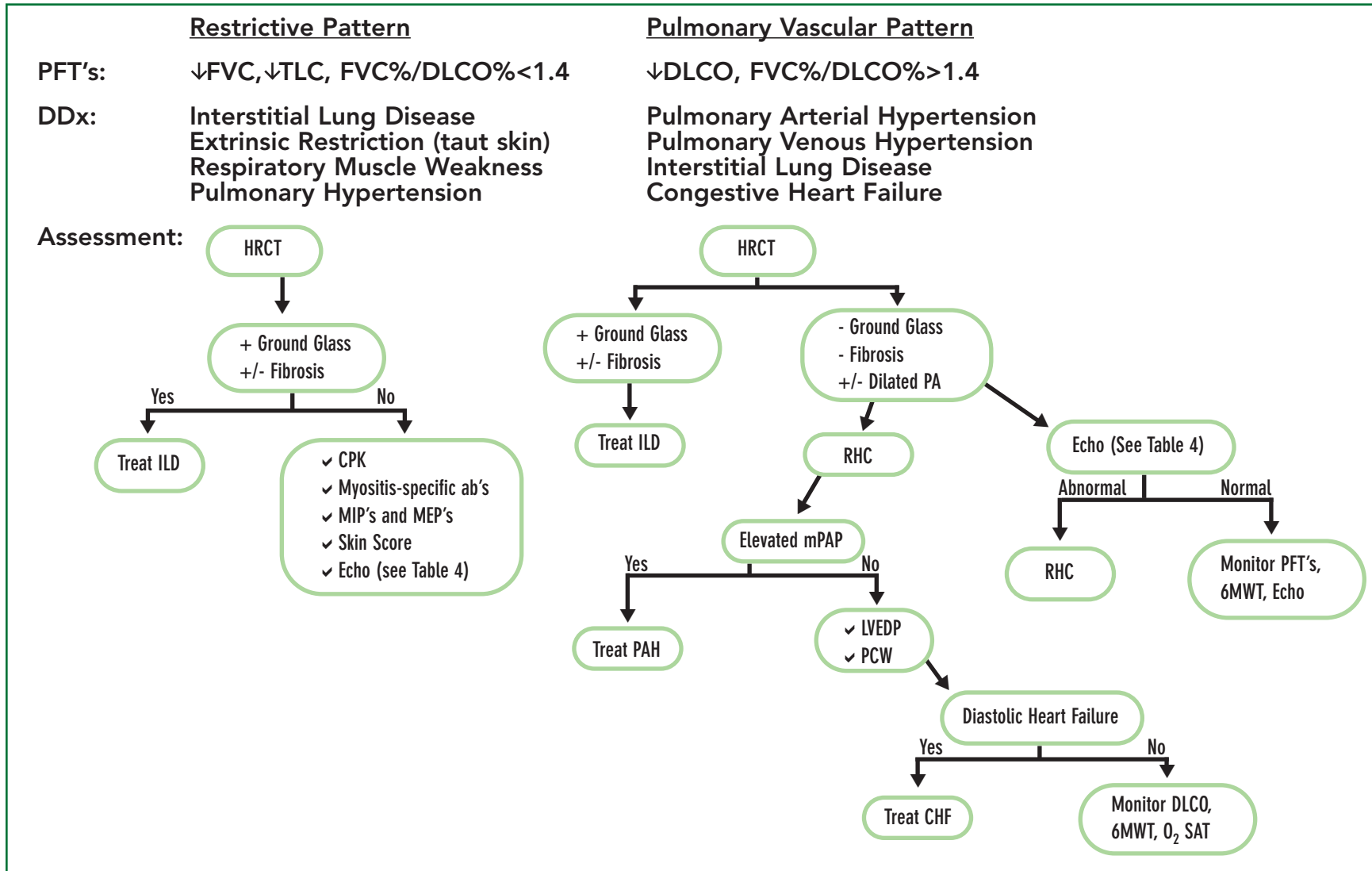


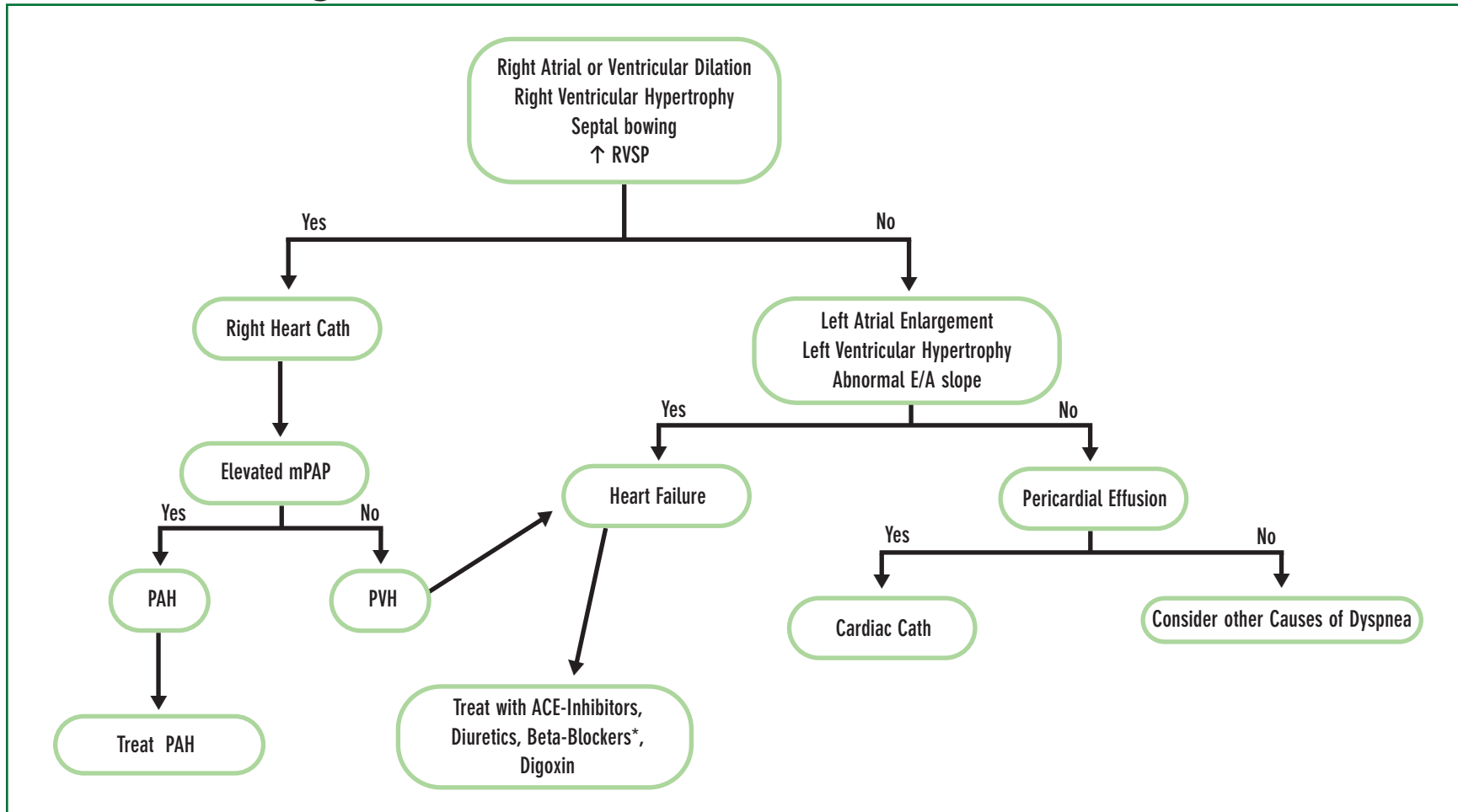
LABORED BREATHING | Dyspnea in the scleroderma patient >> By Richard M. Silver, MD

Major PFT Patterns in SSc with Recommended Assessment



LABORED BREATHING | Dyspnea in the scleroderma patient >> By Richard M. Silver, MD

Echo Findings with Recommended Assessment



* Beta-blockers may exacerbate Raynaud phenomenon